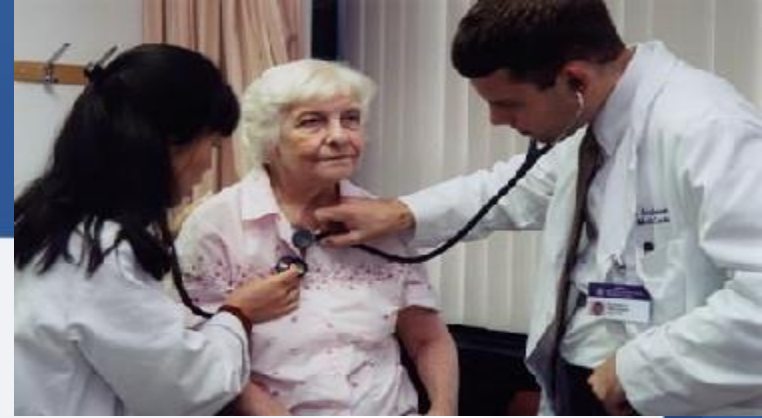



Cardiovascular Patient Assessment

Dr. Gary Mumaugh – Western Physical Assessment

Objectives



- Outline a systematic approach to cardiovascular assessment.
- Differentiate normal from abnormal findings when assessing the cardiovascular system.
- Relate the events of the cardiac cycle to auscultatory findings.

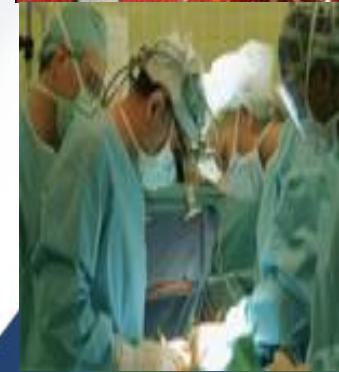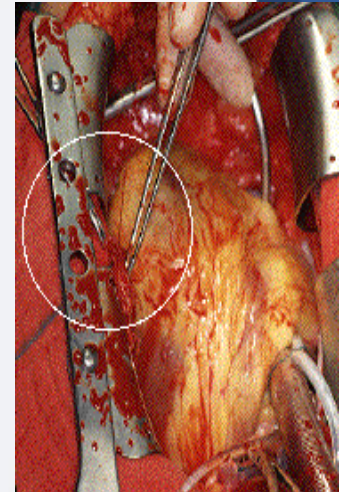
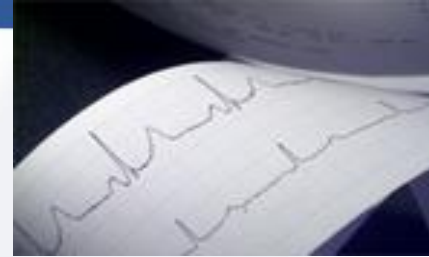Assessing Patient's CV Status

- History & Subjective Data
- Chief Complaint
- Common signs and symptoms of CV disease
- Dyspnea
- Fatigue / Weakness
- Fluid retention
- Syncope / Presyncope
- Palpitations
- Other Symptoms
- Risk Factor
- Social History
- Medication History



History & Subjective Data

- Past Medical history
 - Previous Illness
 - Diagnostic/interventional cardiac procedures
 - Hospitalizations
 - Surgeries
 - Allergies
- AMPLE
 - Allergies, Medications, Past Medical History, Last Eaten, Events Leading

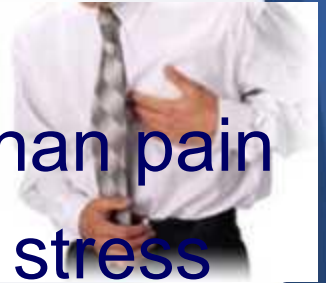

Chief Complaint

Common Signs and Symptoms of CV Disease



- Chest pain (most common CV symptom)
 - Angina
 - often described as “pressure” rather than pain
 - Usually brought by physical/emotional stress
 - Last: 2-5 minutes ; rarely > 20
 - Relieved with rest / NTG (nitroglycerine)

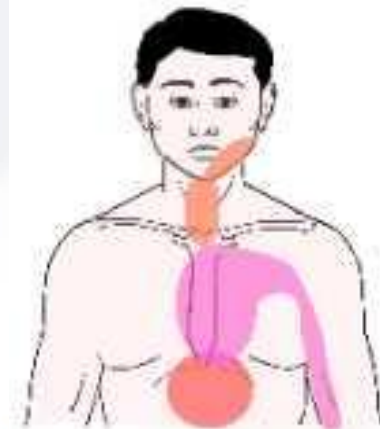


Chief Complaint

Common Signs and Symptoms of CV Disease



- ACS (acute coronary syndrome)
 - Pain similar to angina ; may be more intense
 - Often occurs at rest
 - Usually last >30 minutes; usually > 2 hours
 - Not relieved by rest/NTG; requires analgesic



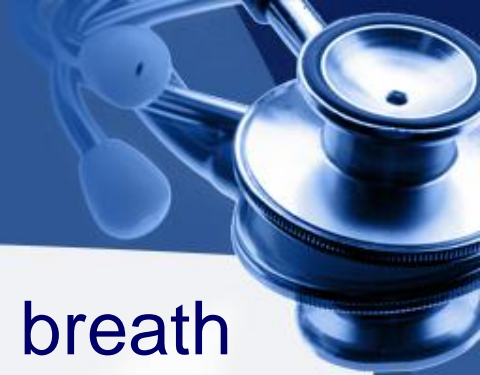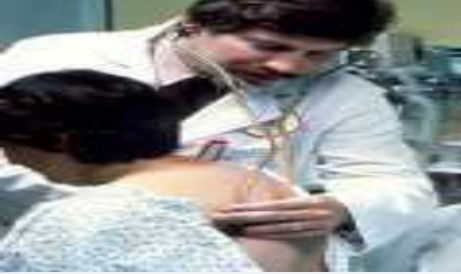Chief Complaint

Common Signs and Symptoms of CV Disease



- **Pericarditis**
 - May mimic ACS; often described as sharp, stabbing, shooting
 - Aggravated by movement
 - Tend to be constant
 - Relieved by sitting up, leaning forward, shallow breathing

Dyspnea



- Subjective sensation of being unable to breath
- Usually cause by congestion from LVF
- Types:
 - Dyspnea on exertion (DOE)
 - Orthopnea : inability to breathe while lying flat
 - Paroxysmal nocturnal dyspnea (PND)
 - Night time episodes of SOB due to lying flat which increases venous return (preload)

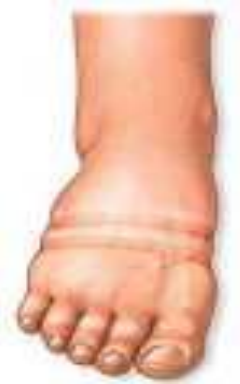Fatigue / Weakness



- Symptom of decreased forward CO
- Usually seen as unusual fatigue at end of normal day previously tolerated
- Exertional fatigue : sense of weakness or heaviness of extremities
- Medications that can cause fatigue:
 - Diuretics : orthostatic hypotension, hypokalemia
 - Beta Blockers, Calcium Channel Blockers, Digoxin, antihypertensive medications

Fluid Retention

- Fluid accumulation in tissues
- Common cardiac causes
 - Heart failure
 - Constrictive pericarditis
 - Restrictive cardiomyopathies
- Weight gain of 2 pounds in 4 days or 3-5 pounds over a month may be indicative of heart failure
- More severe in evening



Syncope / Presyncope



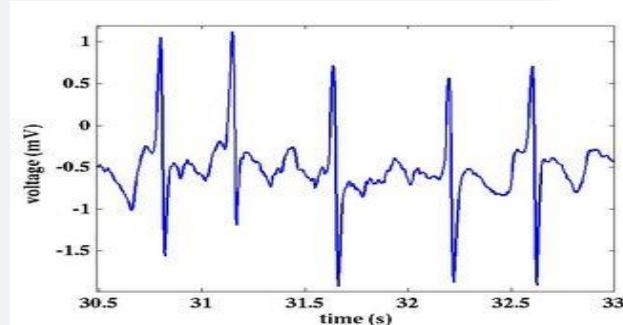
- Temporary loss of consciousness, lightheadedness, dizziness
- Cardiac cause most commonly result of inadequate cardiac output from arrhythmias



Palpitations

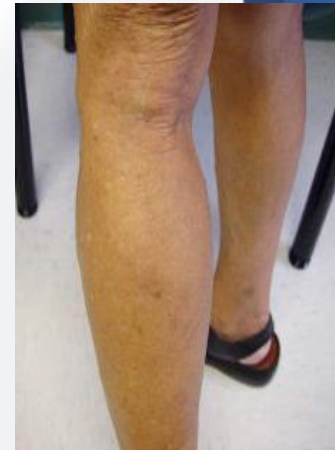

- Awareness of heart beat with sudden changes in rate, rhythm, increased stroke volume
- Associated with : tachycardias, bradycardias, atrial fibrillation, PVCs, aortic and mitral regurgitation, signs of heart failure



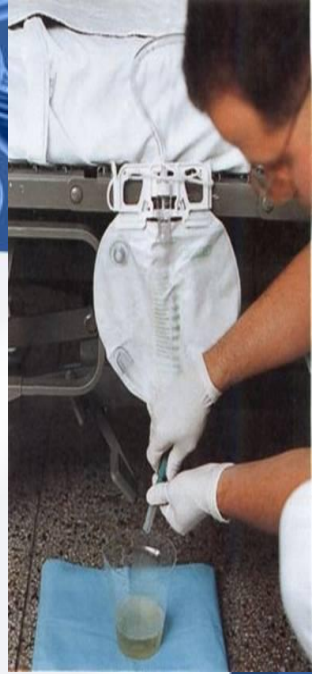
Other Symptoms

- GI
 - Nausea, anorexia, vomiting from RVF, digoxin toxicity, inferior MI
 - Indigestion or flu like symptoms may be sole s/s of MI, especially in elderly or diabetic patient
- Extremity pain
 - Intermittent claudication indicative of PVD due to decreased blood flow to muscles during time of increased demand
 - Ischemia from PVD



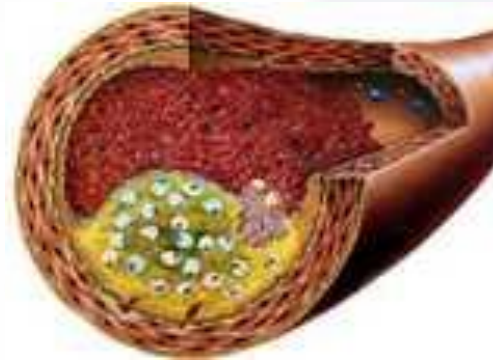Other Symptoms

- Decreased urine output
 - Indicative of heart failure and hypovolemia
 - Look for concomitant weight gain due to CHF
- Nocturia
 - Sign of heart failure
 - Caused by increased preload to heart



Risk Factors

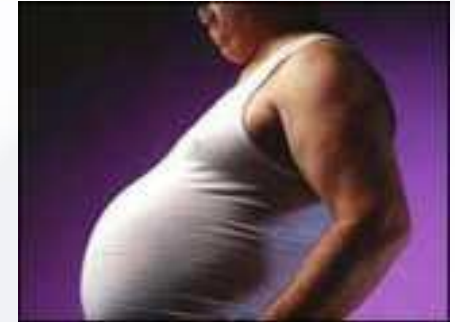- Non-modifiable
 - Age
 - Sex
 - Family history
 - Race



Risk Factors



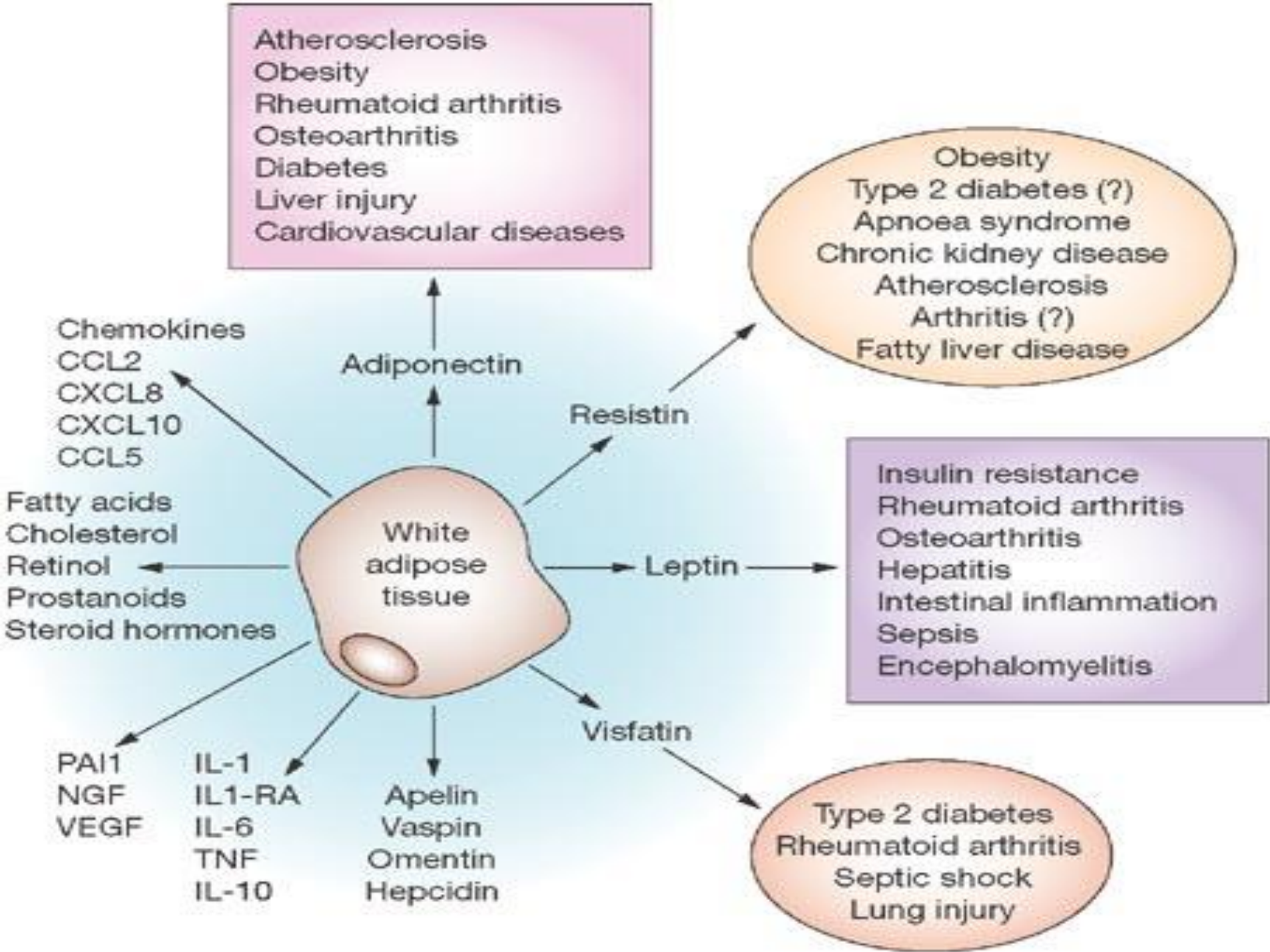
- Modifiable
 - Cigarette smoking
 - Hypertension
 - Hyperlipidemia
 - Physical inactivity
 - Diabetes
 - Stress
 - Obesity



FAT : Adipose Tissue



- Endocrine function
- “Adipokines”
 - Leptin
 - Pro-thrombotic
 - Anti-inflammatory
 - Satiety to hypothalamus
 - Resistin
 - Hormone making tissue insulin resistant
 - Type II DM
 - Adiponectin
 - Counteracts negative effects of other hormones



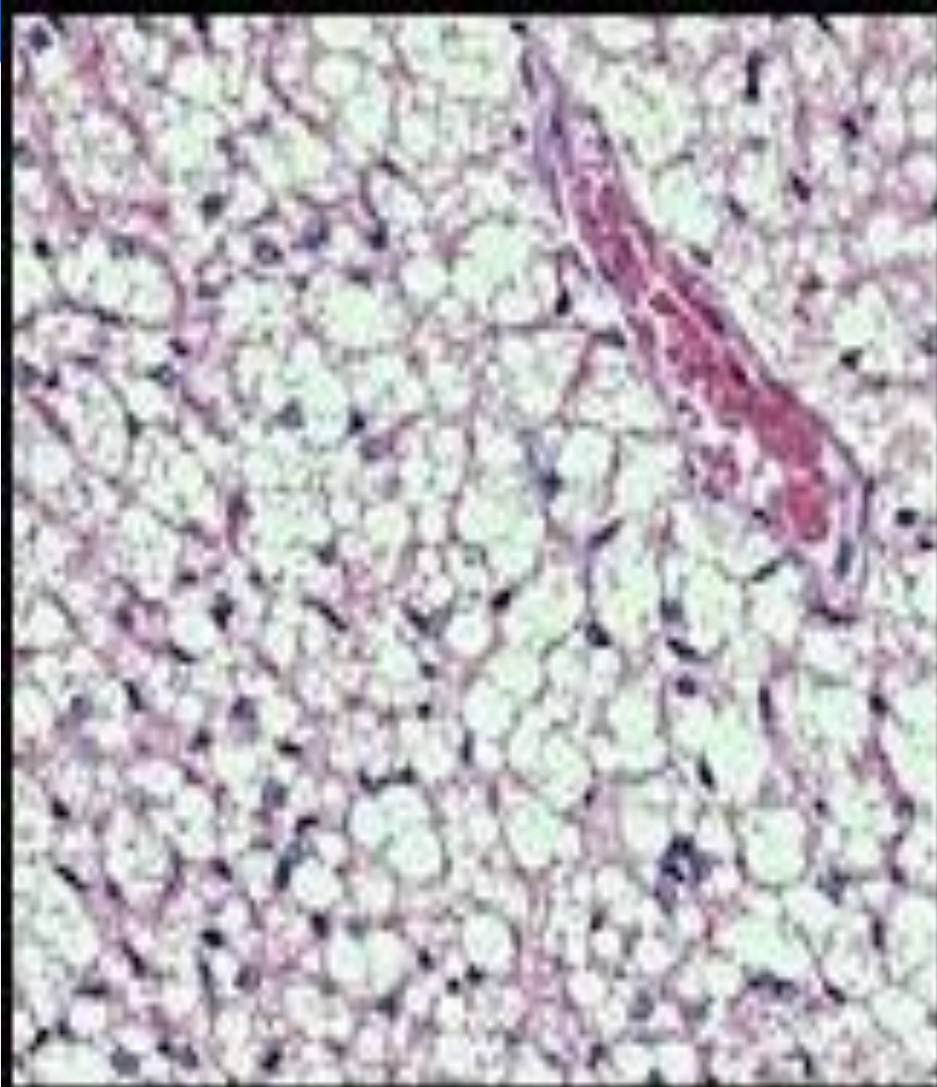Brown Fat vs. White Fat




White vs. Brown Fat

"Apple" vs. "Pear"





GOOD BROWN FAT



BAD WHITE FAT



White adipose tissue

White adipocytes contain single large lipid droplet, few mitochondria

Secretes adipose derived hormones, that regulate insulin sensitivity and satiety

Stores excess energy as triglycerides, releases fatty acids during fasting periods

Brown adipose tissue

Brown adipocytes contain multiple small lipid droplets, rich in mitochondria

Densely vascularized and innervated by sympathetic nerve endings

Expression of uncoupling protein 1

Dissipates chemical energy (mainly from fatty acids) to generate heat

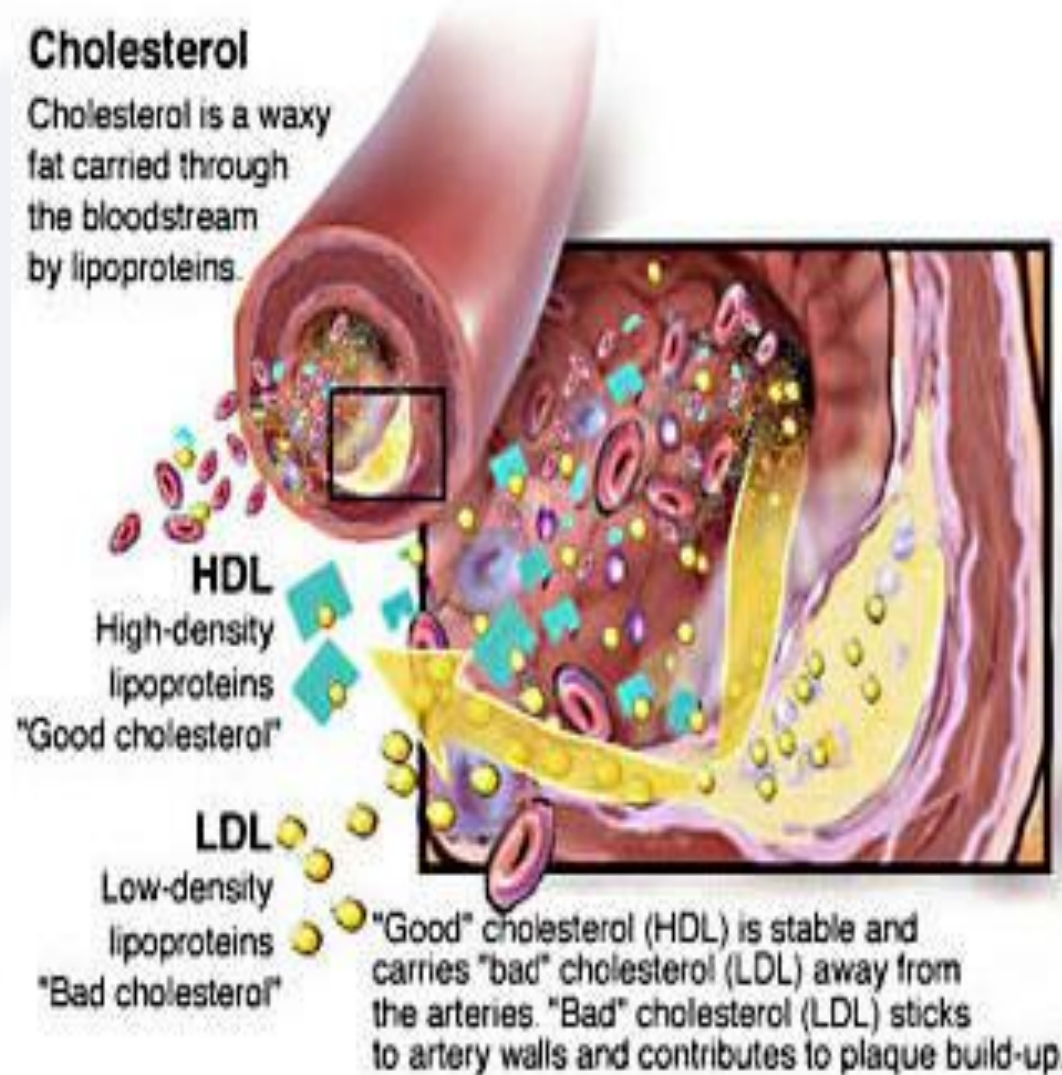
Cholesterol Level : AHA Recommendation



- Total Cholesterol
 - < 200 mg/dL
 - best
 - 200 – 239
 - borderline high
 - 240 mg/dL and above
 - 2X risk of CAD

Cholesterol

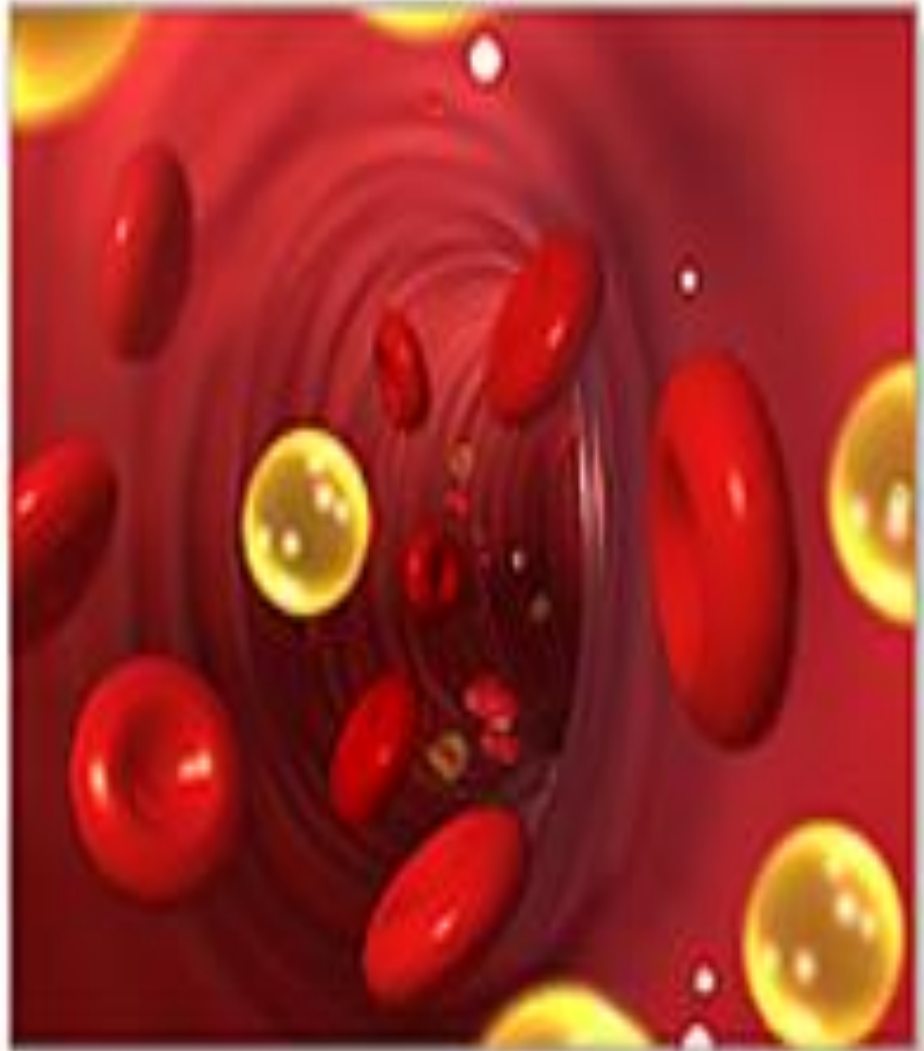
Cholesterol is a waxy fat carried through the bloodstream by lipoproteins.



Cholesterol Level : AHA Recommendation



- HDL Cholesterol
 - < 40 mg/dL (men)
 - < 50 mg/dL (women)
 - > 60 mg/dL
 - cardioprotective

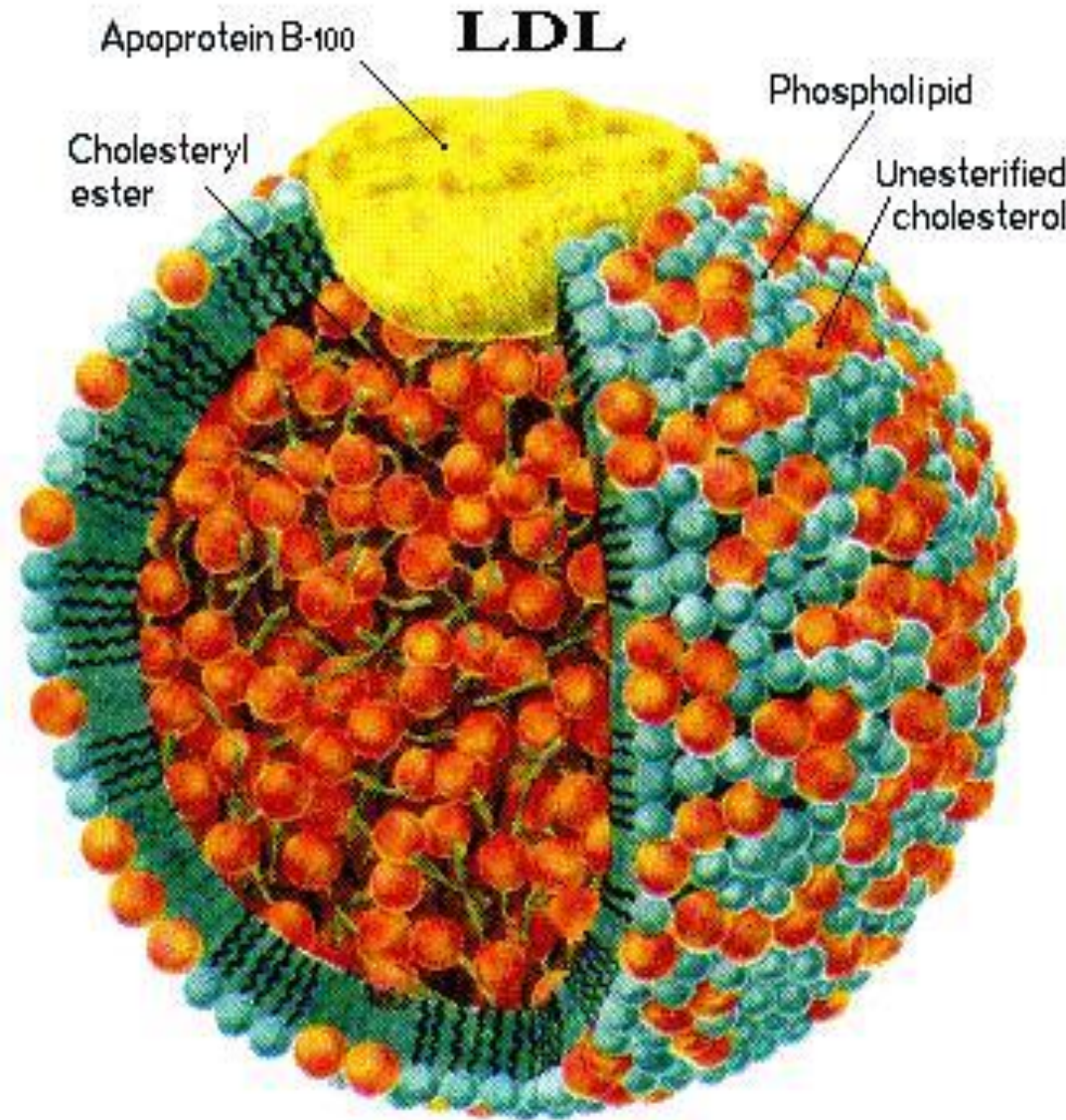


Cholesterol Level : AHA Recommendation



- **LDL Cholesterol**

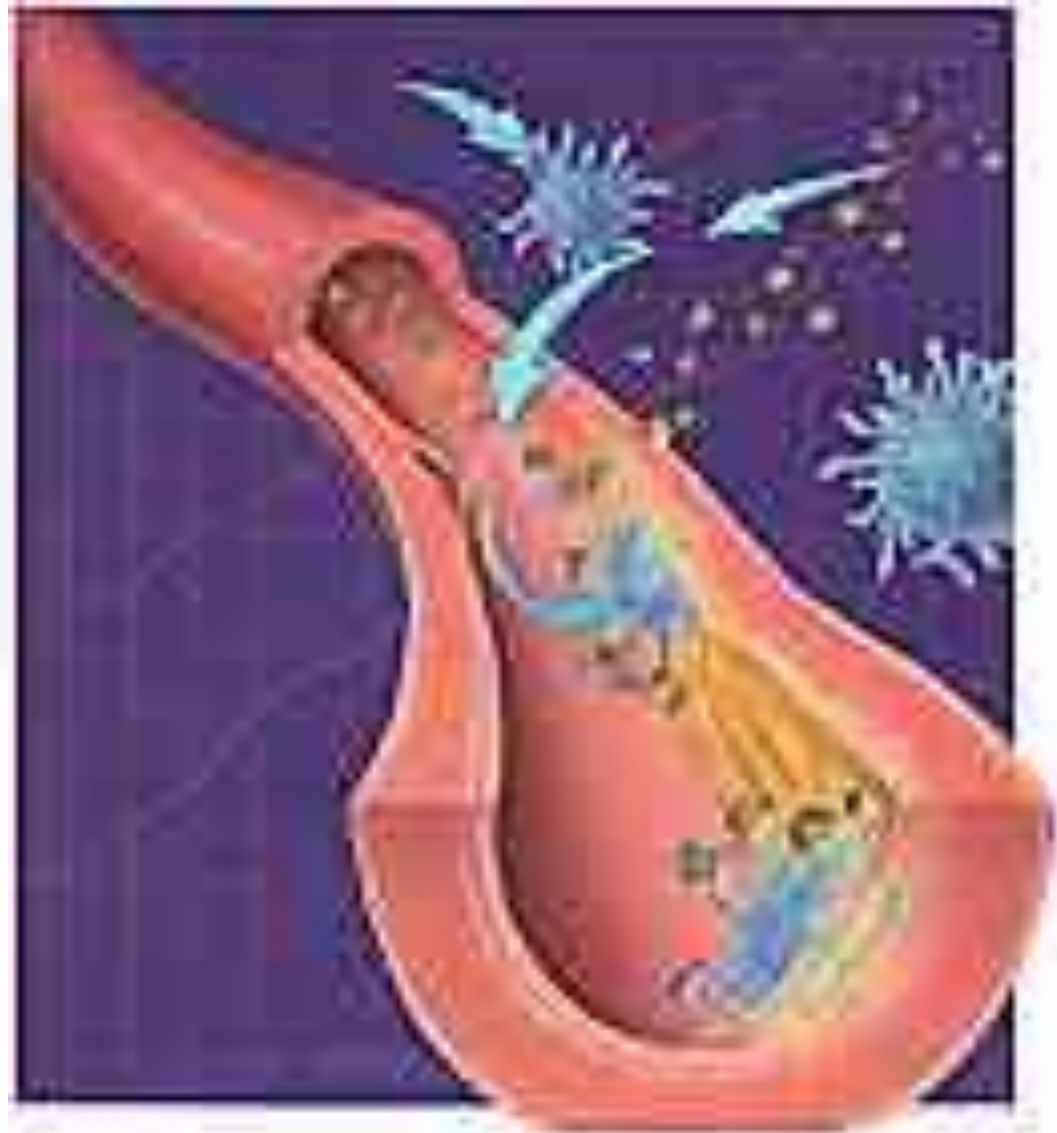
- < 100 mg/dL
 - Optimal
- 100 – 129 mg/dL
 - Near or above optimal
- 130 – 159 mg/dL
 - Borderline
- 160 – 189 mg/dL
 - High
- 190 mg/dL
 - Very high



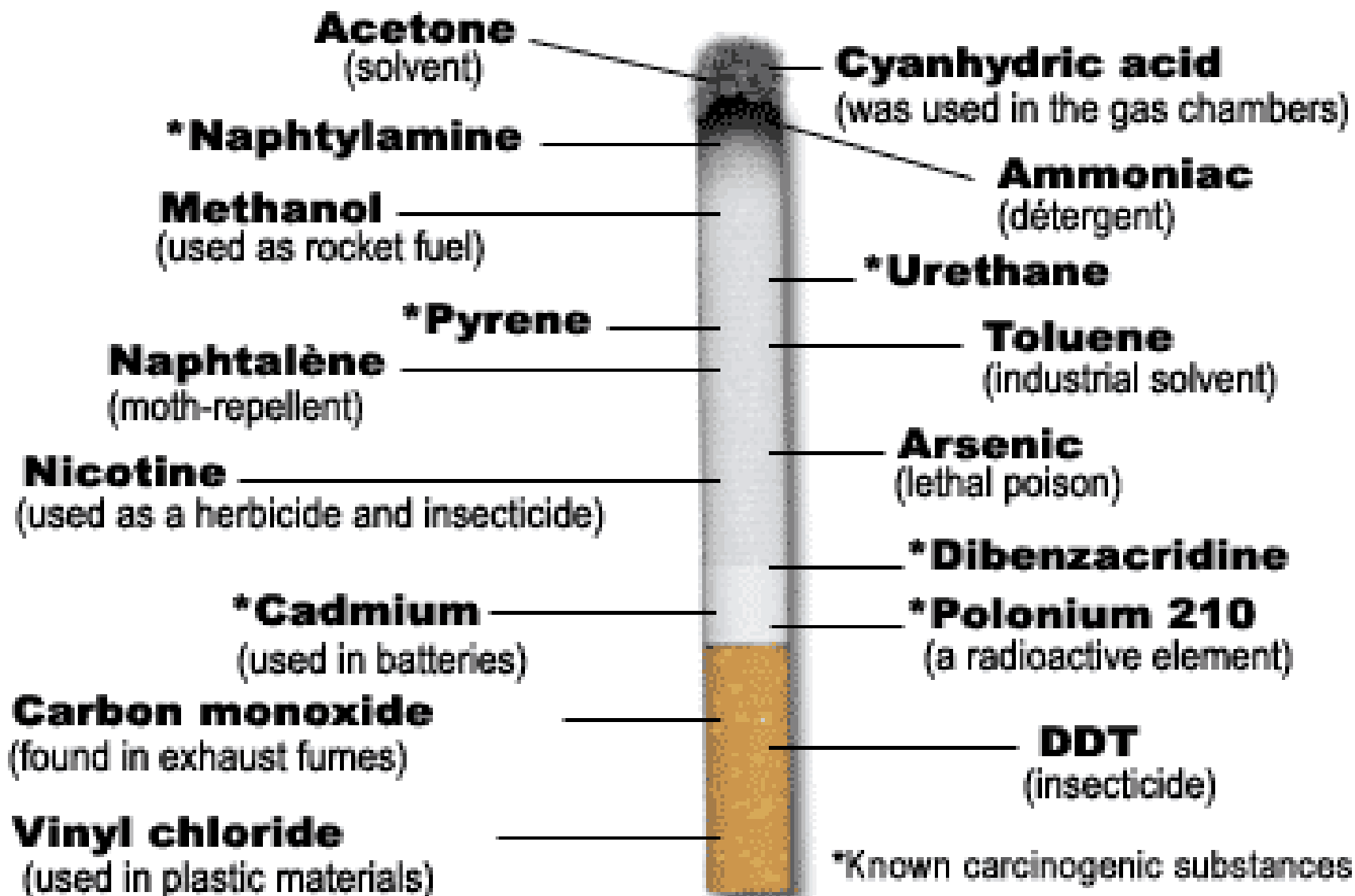
Cholesterol Level : AHA Recommendation



- Triglyceride
 - < 150 mg/dL
 - Normal
 - 150 – 199 mg/dL
 - Borderline high
 - 200 – 499mg/dL
 - High
 - 500 mg/dL and above
 - Very high




DANGER POISON !



STOP SMOKING!

Sphygmomanometer

column of mercury
indicating pressure
in mm Hg



No sounds
(artery is closed)

Sounds heard
(artery is opening
and closing)

No sounds
(artery is open)

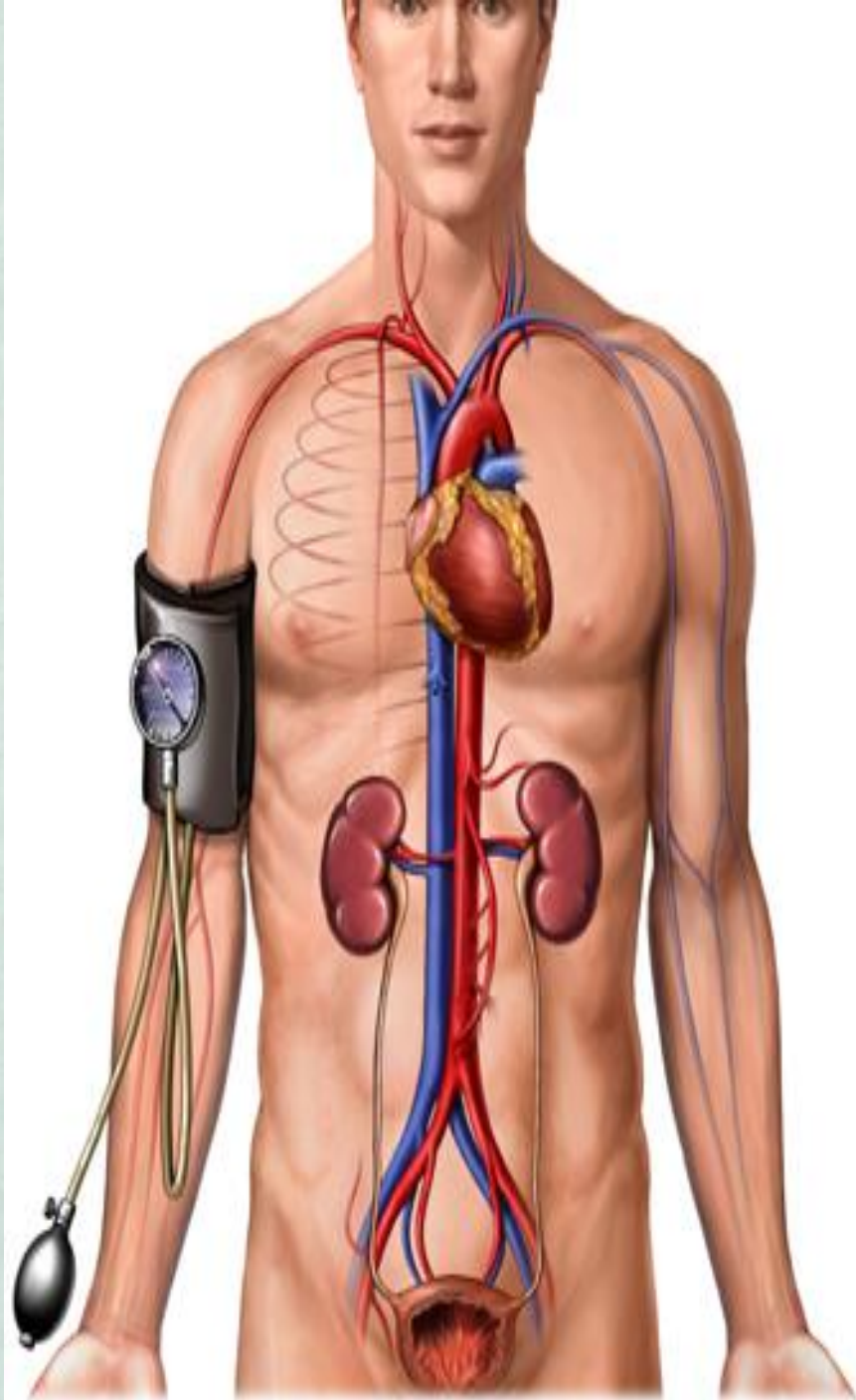
inflatable
rubber cuff

artery

air valve

squeezable bulb
inflates cuff with air

sounds are heard
with stethoscope



Know you're A-B-C Numbers




- Hemoglobin A1c
 - Measures an average BS over 3 months
 - Goal : under 7%
 - Prefer under 6.5%
- Blood Pressure
 - < 130/80 mmHg
- Cholesterol
 - Total : < 200 mg/dl
 - HDL : > 45 mg/dl in men ; 55 mg/dl in women
 - Triglycerides : < 150 mg/dl

Know you're A-B-C Numbers



A1c: Approximate conversion to blood sugar levels



	A1c Value	Glucose mmol/L (mean)	Glucose mg/dL (mean)
	12.0 %	19.5	345
	11.0 %	17.5	310
Action Suggested	10.0 %	15.5	275
	9.0 %	13.5	240
Caution	8.0 %	11.5	205
Excellent	7.0 %	9.5	170
	6.0 %	7.5	135




Adapted from :American Diabetes Association Standards of Medical Care in Diabetes
Diabetes Care 28:S4-S36, 2005

Social History

- Alcohol intake
- Dietary pattern: caffeine , salt intake
- Cocaine
- Educational level
- Medication History

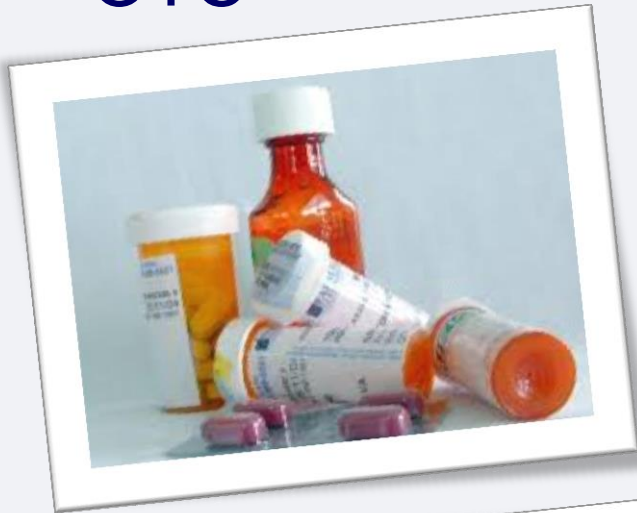

Salty Foods



Medication History

- Prescribed drugs
- OTC

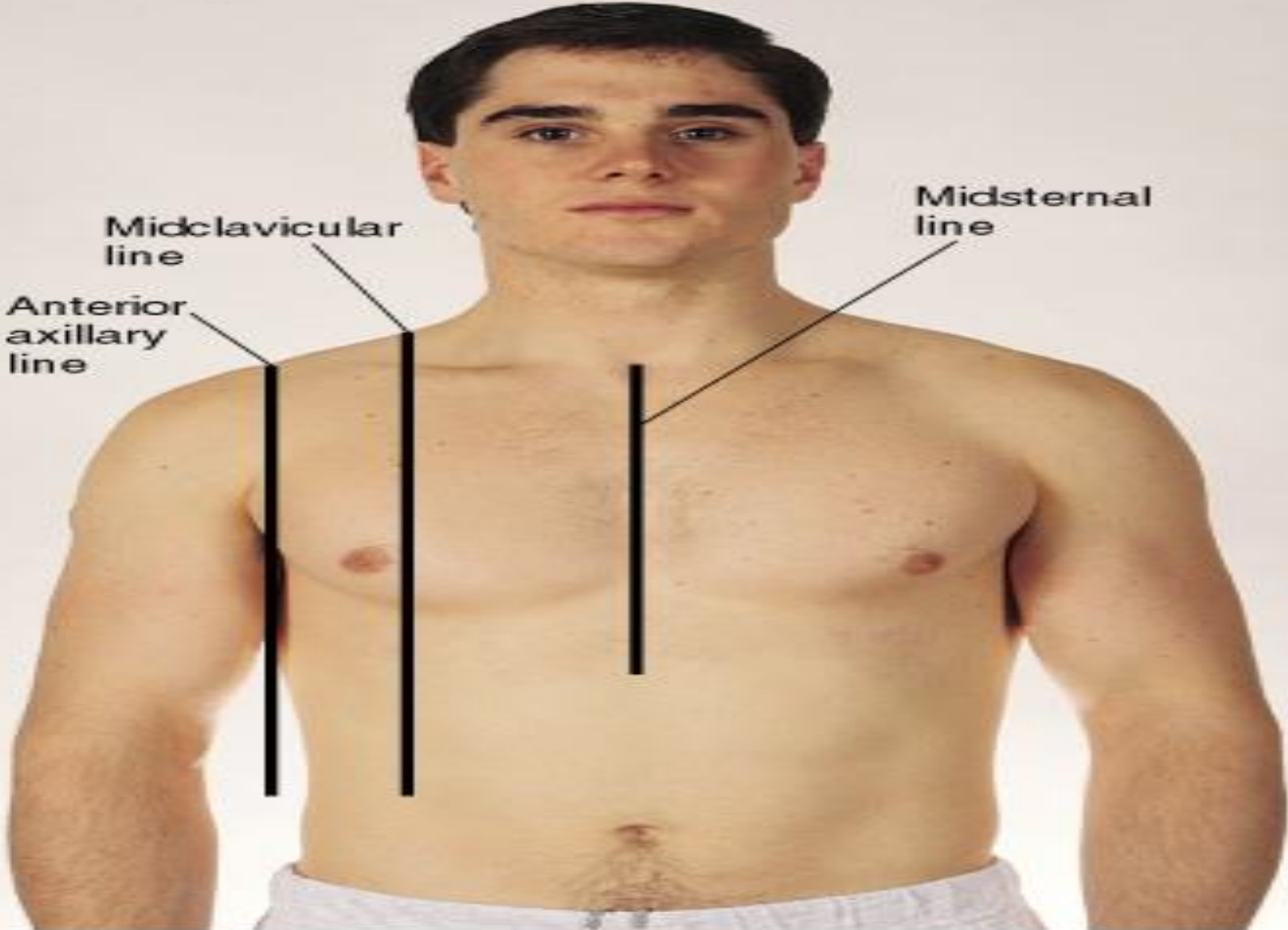


Cardiac Examination



- Includes vital signs and chest examination
- Remember 4 basic components of examination
 - Inspection
 - Palpation
 - Percussion
 - Auscultation
- Pay attention to many of the same things as with chest / lung exam (chest shape, etc.)
- Shortness of breath (@ rest or walking)
- Sitting upright? Able to speak?
- ? Visible pulse on chest wall
 - (Rare – Vigorous Ventricle Contraction)

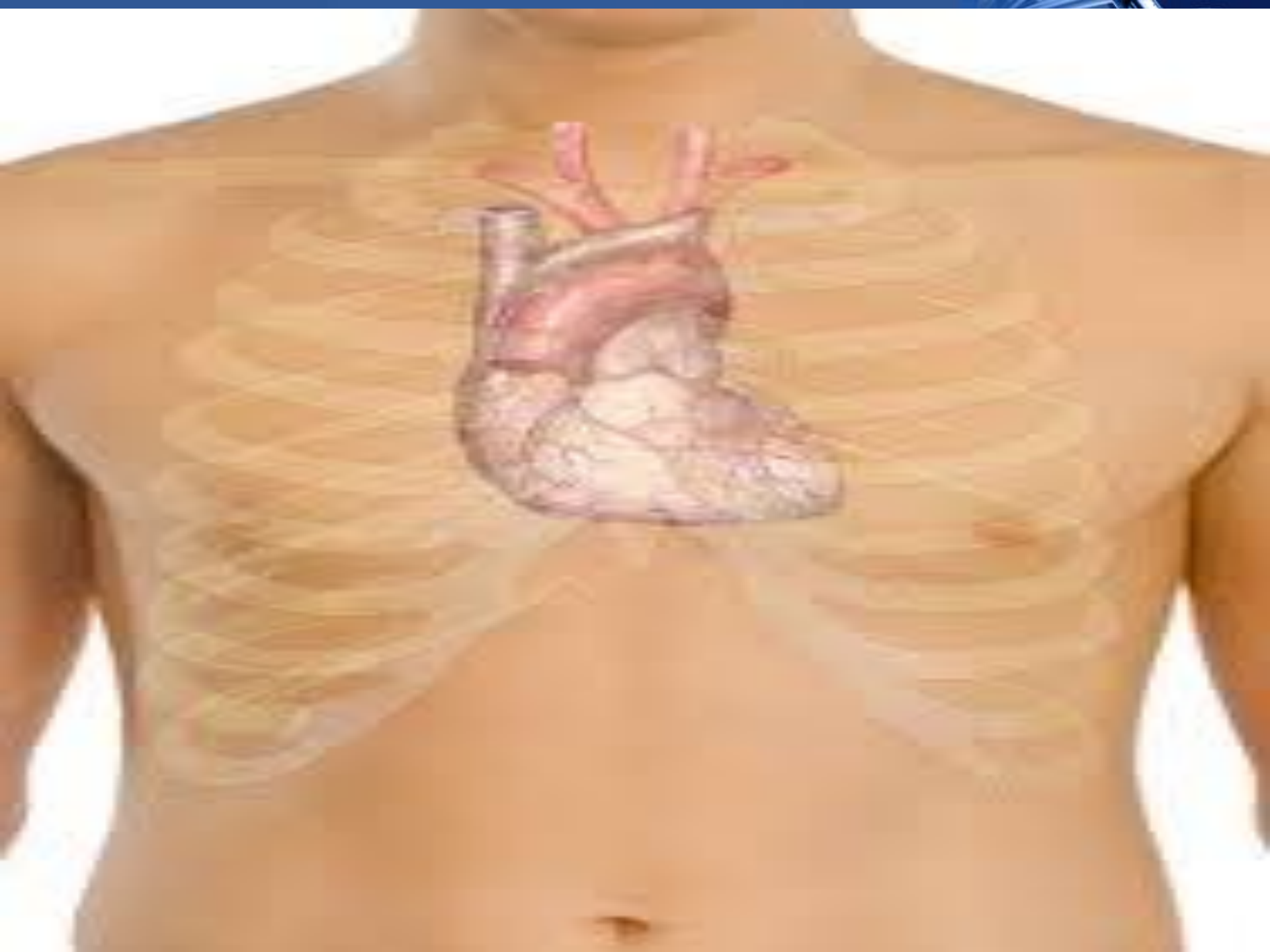Know Your Surface Landmarks



Anterior axillary line

Midclavicular line

Midsternal line



Suprasternal notch
Sternal end of first rib
Second rib
Brace between deltoid and pectoralis major
Outer end of clavicle
Coracoid process
Acromioclavicular joint
Axillary nerve

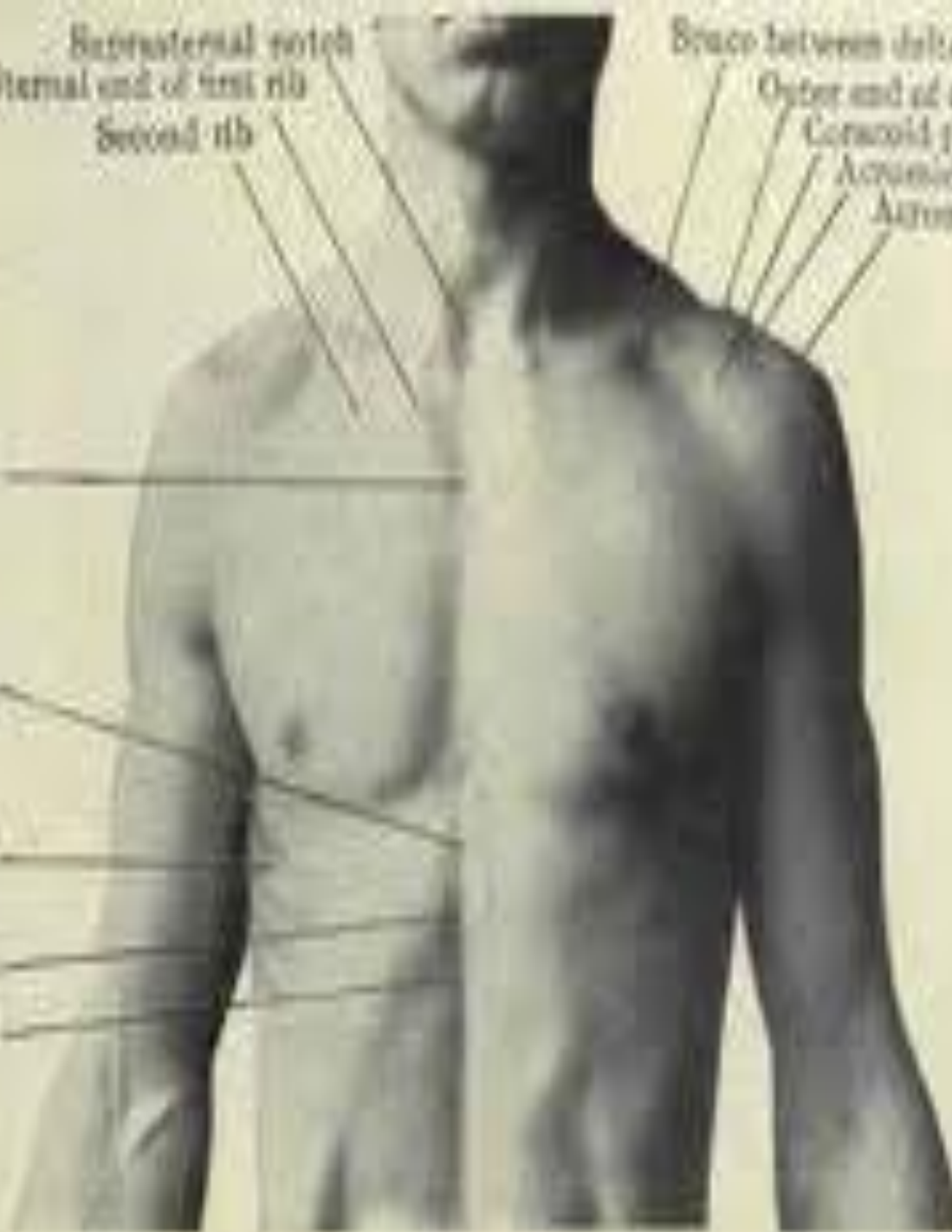Angle of sternum
opposite second rib

Xiphisternal
articulation

Insertions of serratus
anterior muscle

Tip of acromion process

Intercostal depression



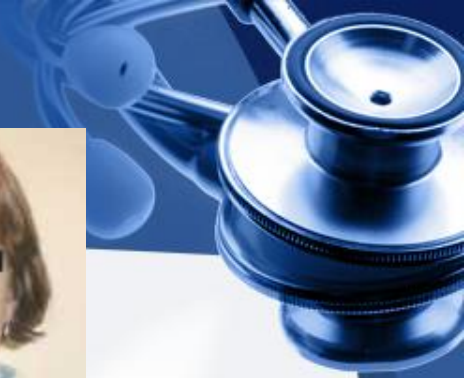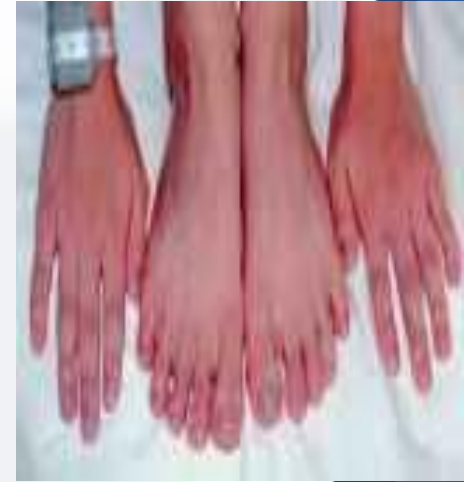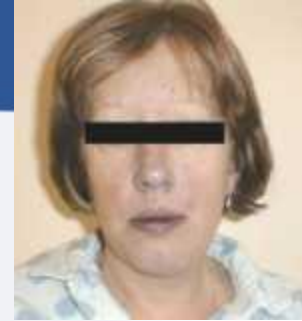Physical Examination



- Inspection
 - Color
 - Extremities
 - Skin changes
- Palpation
 - Edema
 - Pulses
- Percussion
- Auscultation
 - Blood Pressure
 - Heart Sounds / Murmurs
 - Extra Heart Sounds

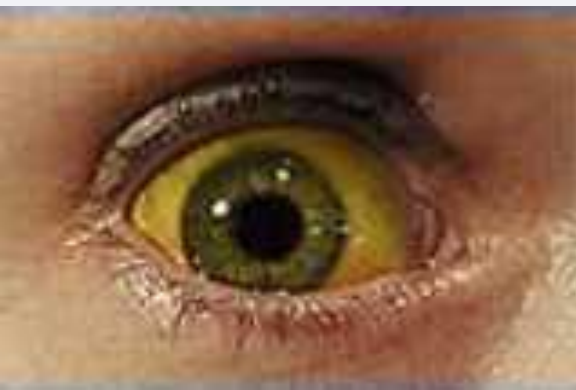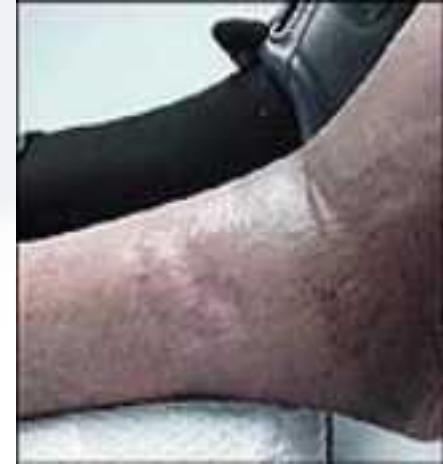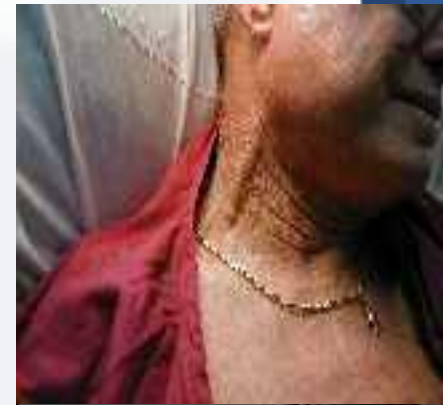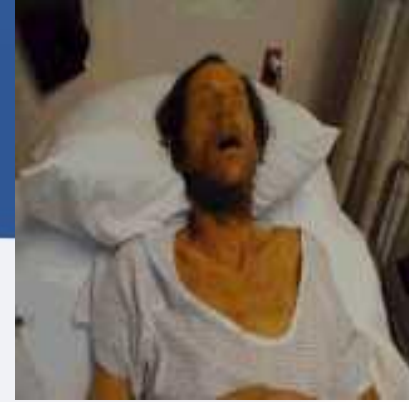Inspection

- General appearance
- Color
 - Cyanosis
 - Central Cyanosis
 - Decreased SaO₂ – usually < 80%
 - Indicates cardiopulmonary disease
 - Seen in buccal mucosa, conjunctiva
 - Peripheral Cyanosis
 - Reduced blood flow to extremity
 - Seen on tip of nose, ears, distal extremities
 - Indicates low CO as in late heart failure or shock



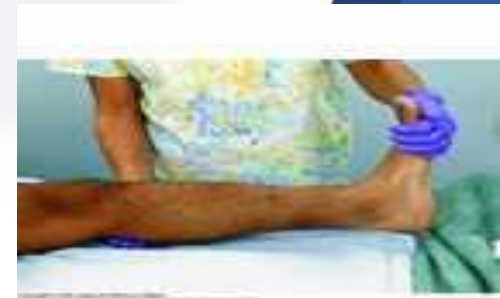Inspection

- Jaundice
 - Best seen in sclera
 - Seen in late heart failure caused by hepatic impairment
- Pallor
 - Indicates anemia or increased SVR
 - Inspect palm of hands
- Jugular Venous Pressure



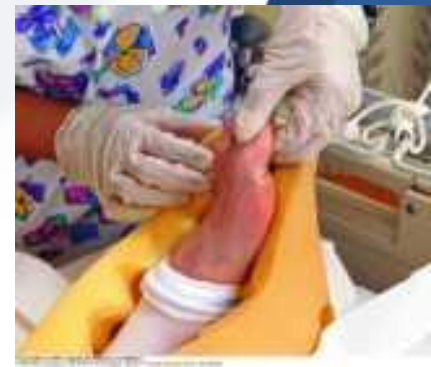Inspection

- Extremities
 - Arterial insufficiency
 - 4 P's of blocked arteries
 - Pulseless
 - Pallor
 - Pain
 - Paralysis



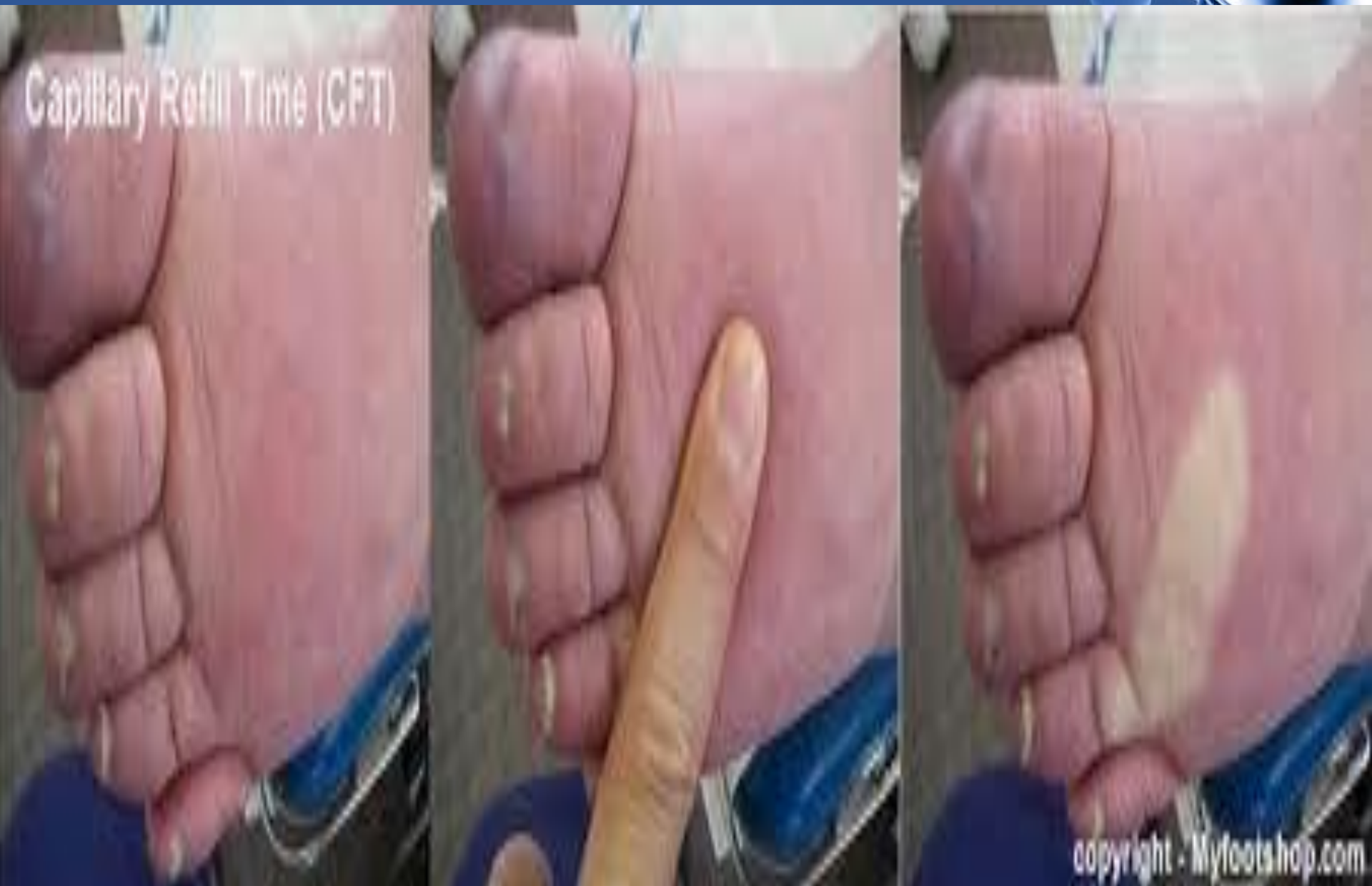Inspection

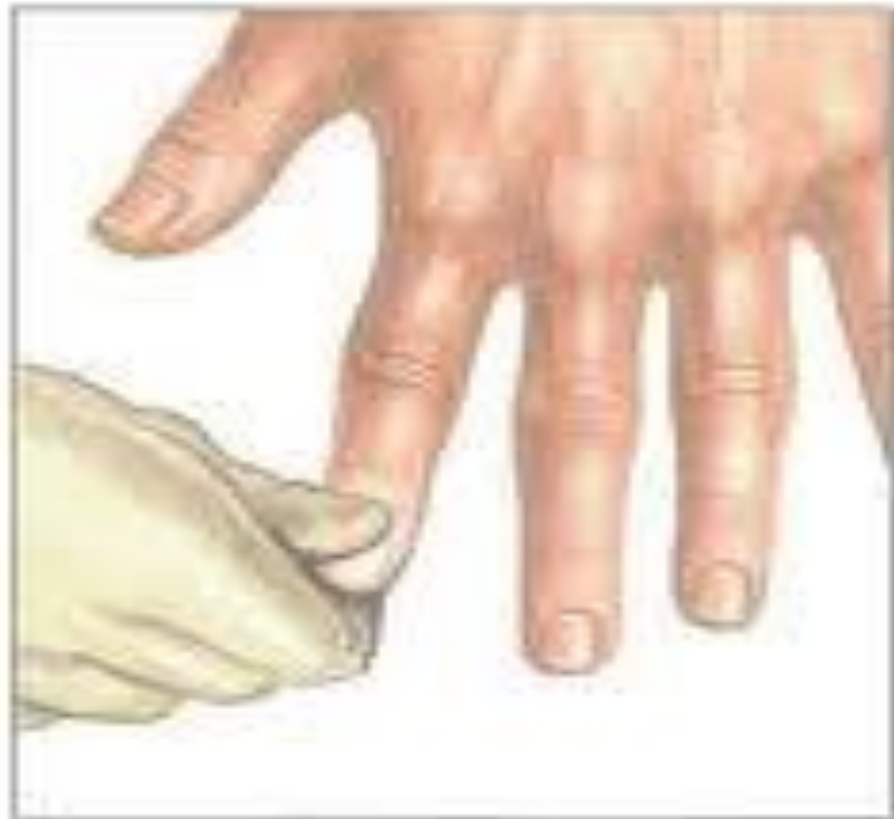- Skin Changes
 - Taut, skinny, scaly, atrophied
 - Ulcerations common above lateral malleolus, pale extremely painful
 - Loss of hair – especially lower leg
- Delayed capillary filling
 - Provides estimate of peripheral blood flow
 - Normal return < 2 seconds ; if more indicates low CO, low volume, low SVR





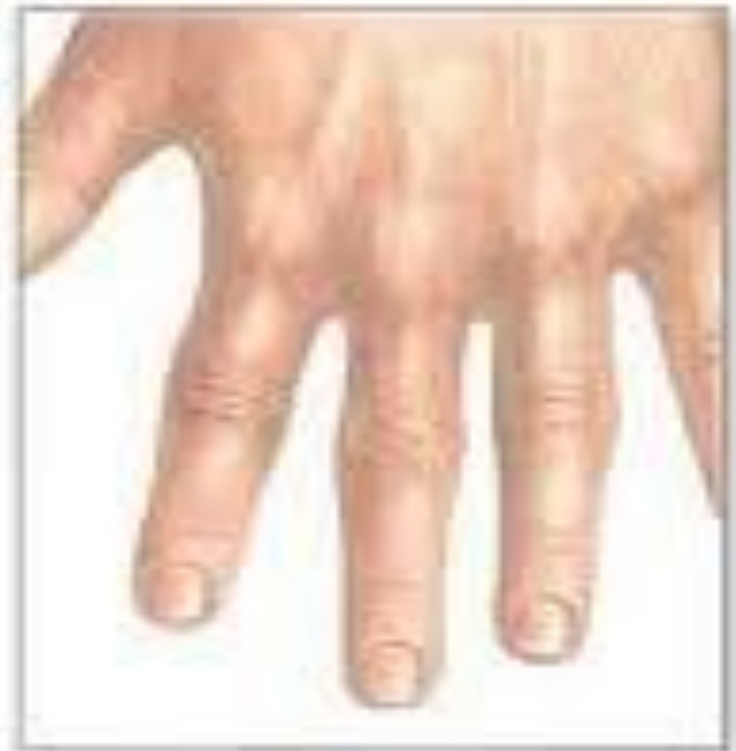Capillary Refill Time (CRT)





Pressure is applied to nail bed until it turns white

Blood returned to tissue



Inspection



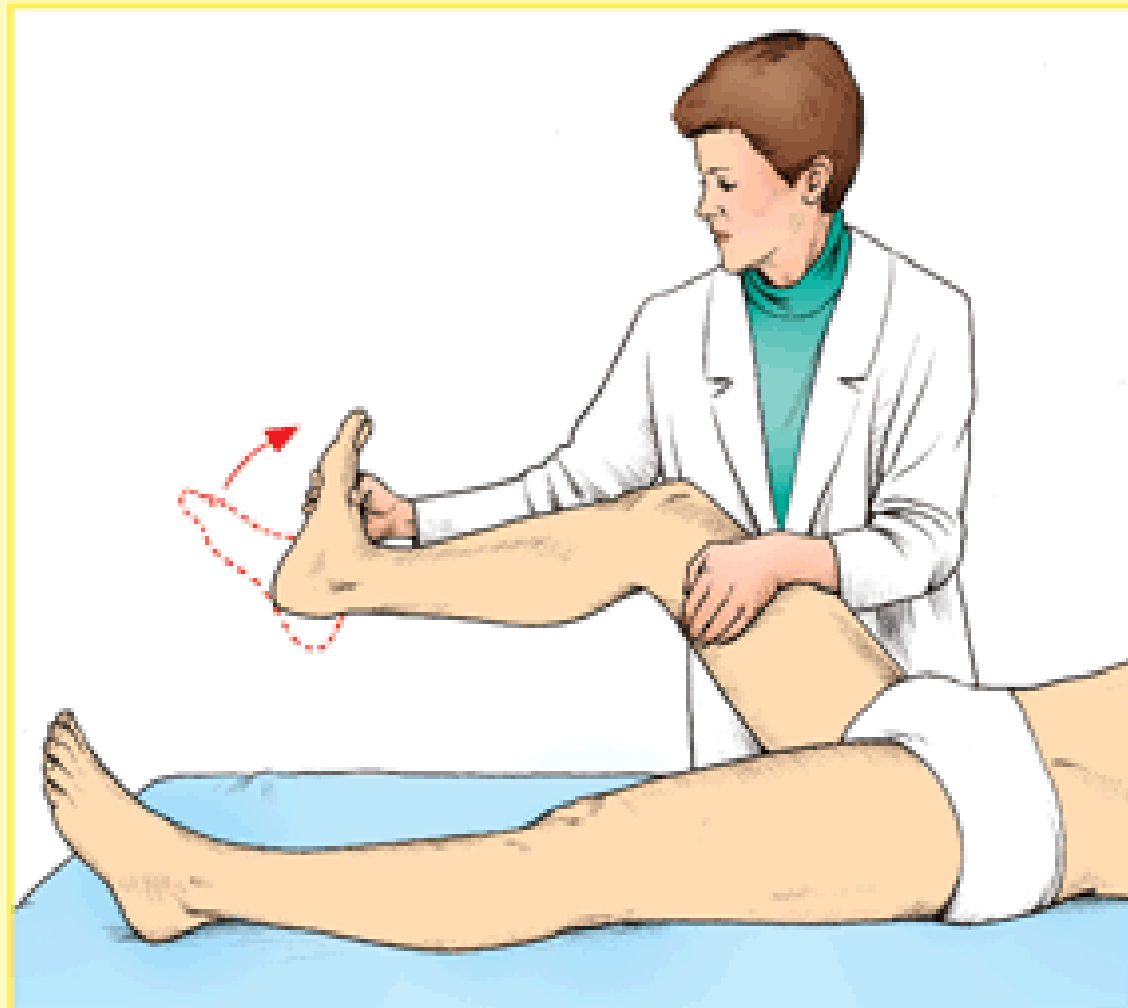
- Nails
- Venous insufficiency
- Thrombophlebitis
 - Homan's Sign – calf pain with dorsiflexion

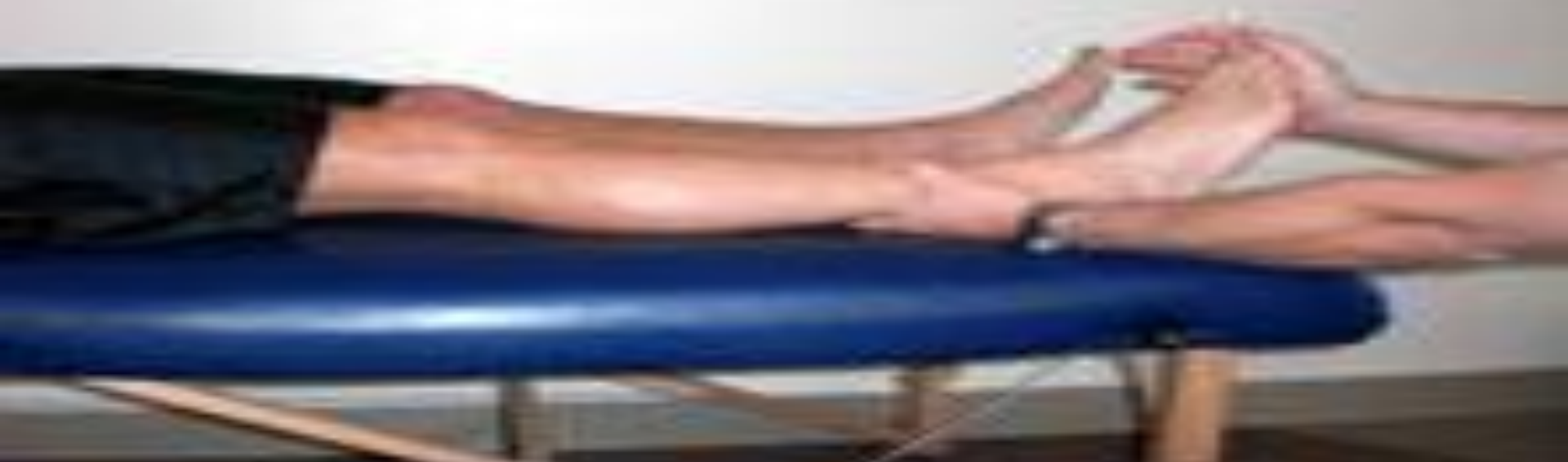



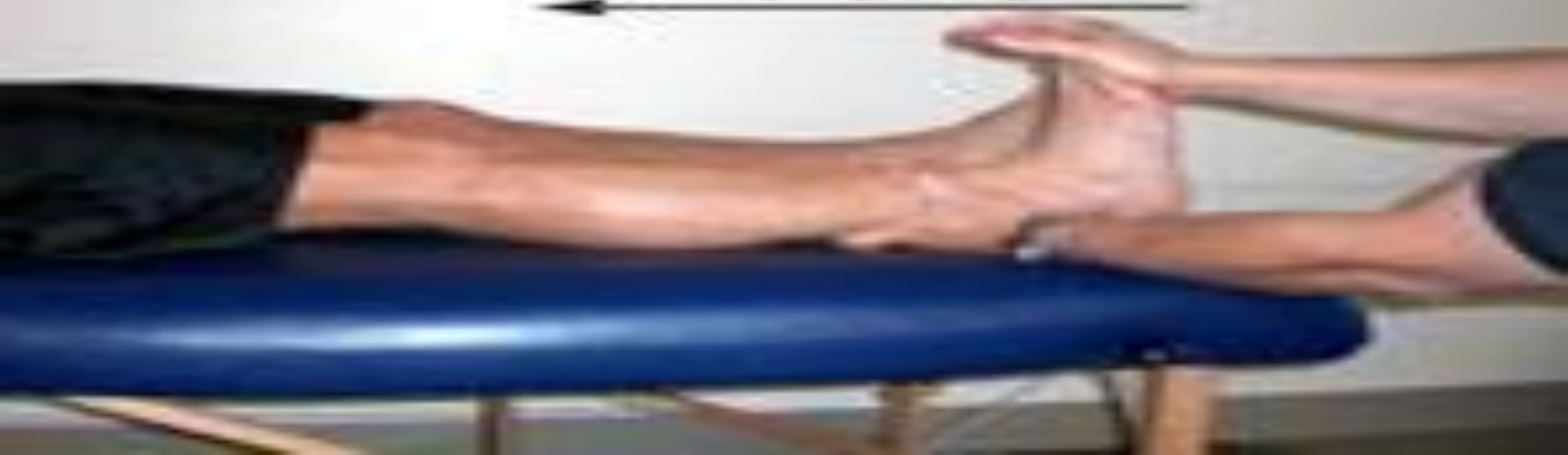ELICITING HOMANS' SIGN

To elicit Homans' sign, first support the patient's thigh with one hand and his foot with the other. Bend his leg slightly at the knee; then firmly and abruptly dorsiflex the ankle. Resulting deep calf pain indicates a positive Homans' sign. (The patient may also resist ankle dorsiflexion or flex the knee involuntarily if Homans' sign is positive.)





Dorsiflex



Palpating the Chest Wall



- Using the finger pads, palpate for **heaves and lifts** from abnormal ventricular movements
- Using the palm of the hand, palpate for thrills or turbulence transmitted to the chest wall by damaged heart valves
- Palpate the chest wall in the aortic, pulmonic, apical areas and mediastinum

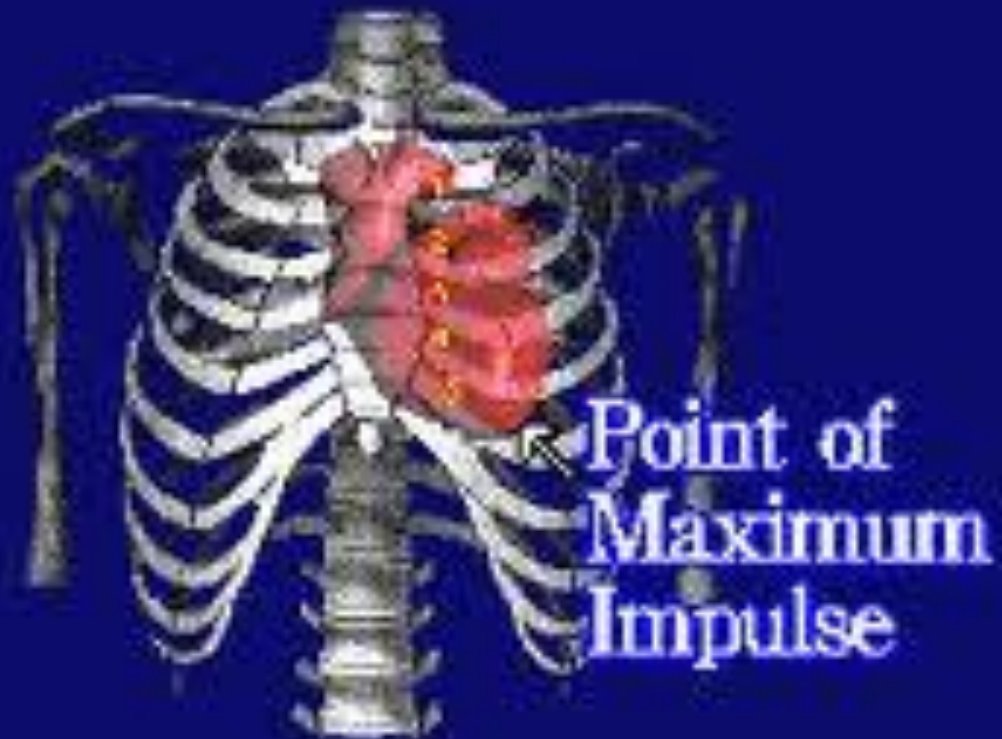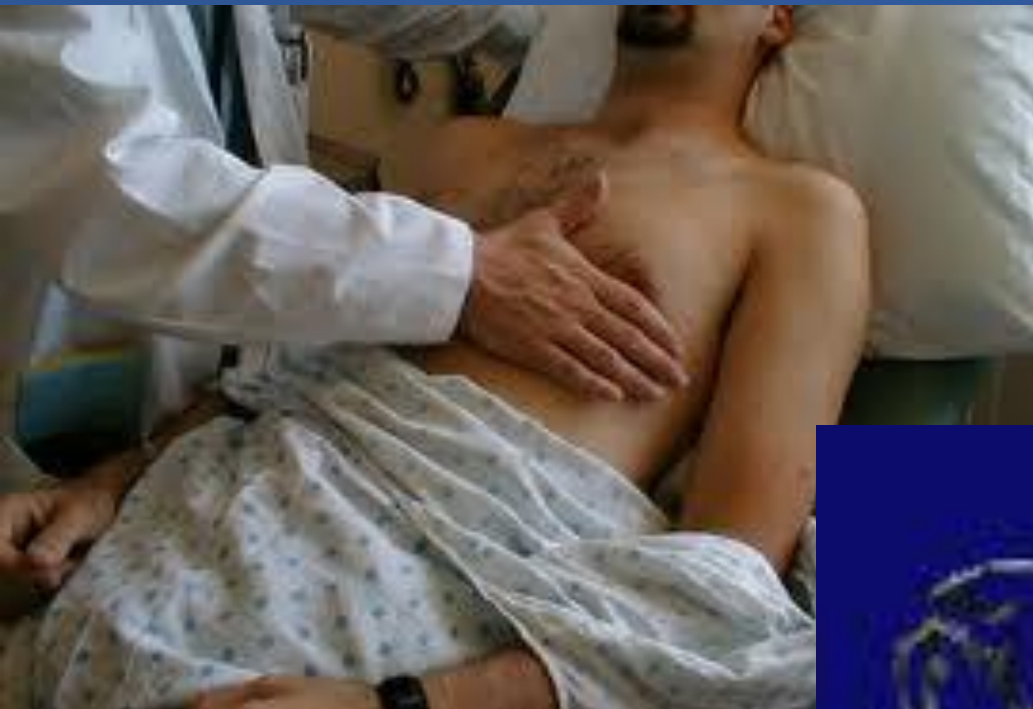Assessing the PMI

Point of Maximal Impulse

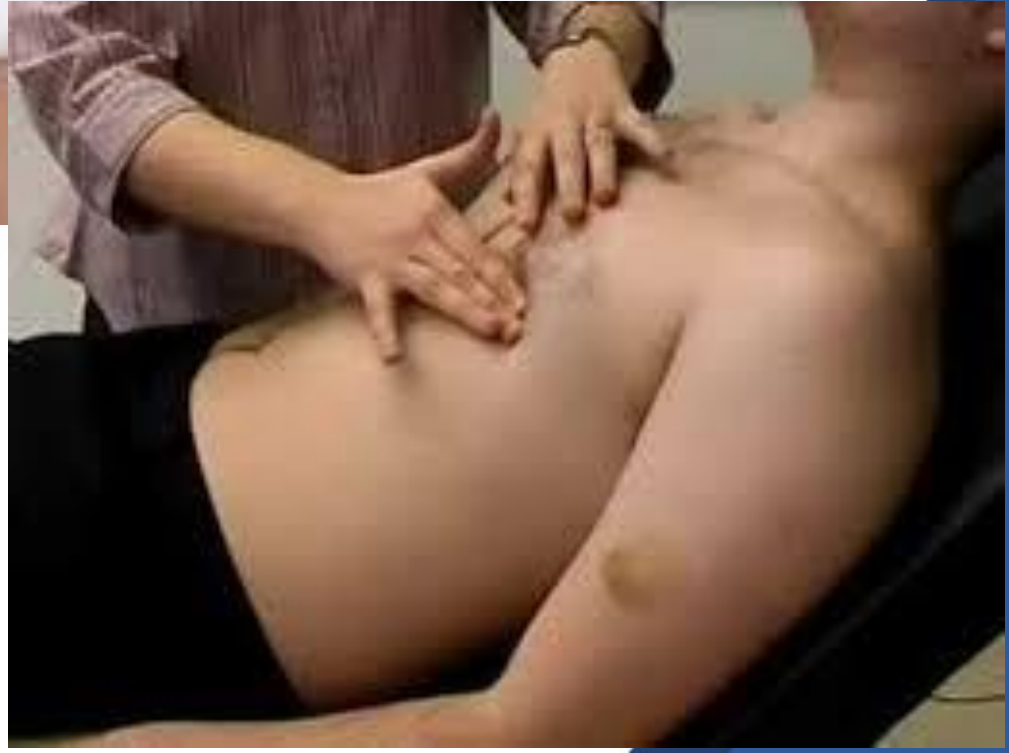
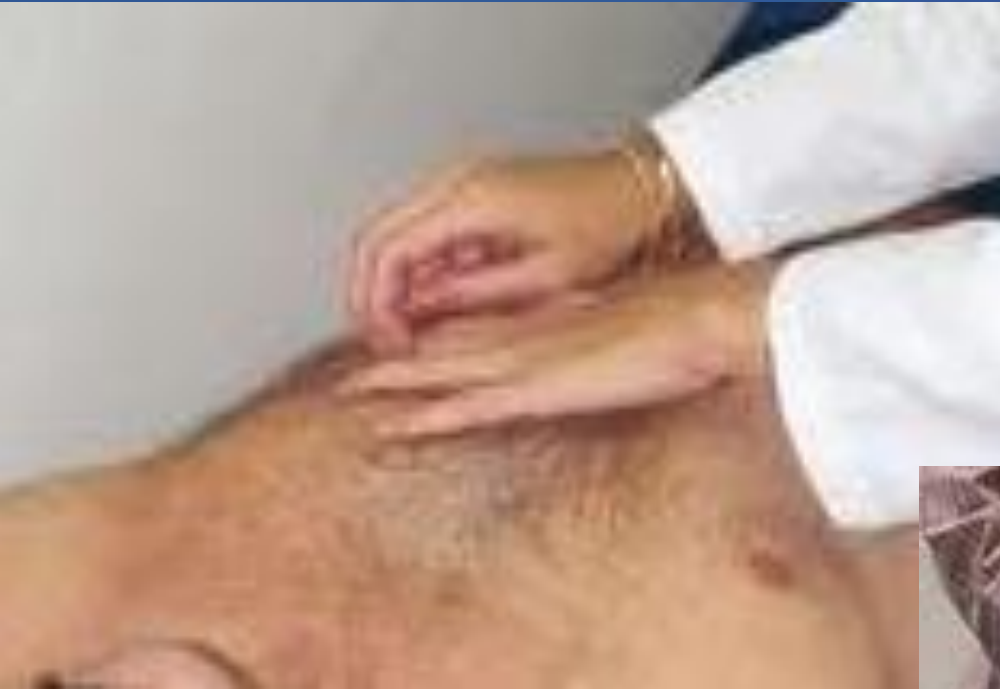

- Inspect the left anterior chest for a visible PMI
- Using finger pads, palpate the apex for the PMI
- The PMI may be
 - Tapping – normal
 - Sustained – suggests LV hypertrophy from HTN or aortic stenosis
 - Diffuse – suggests dilated ventricle from CHF or cardiomyopathy
- Locate the PMI by interspace and distance from the midsternal line
- Assess location, amplitude, duration

Point of Maximal Impulse



Percussion



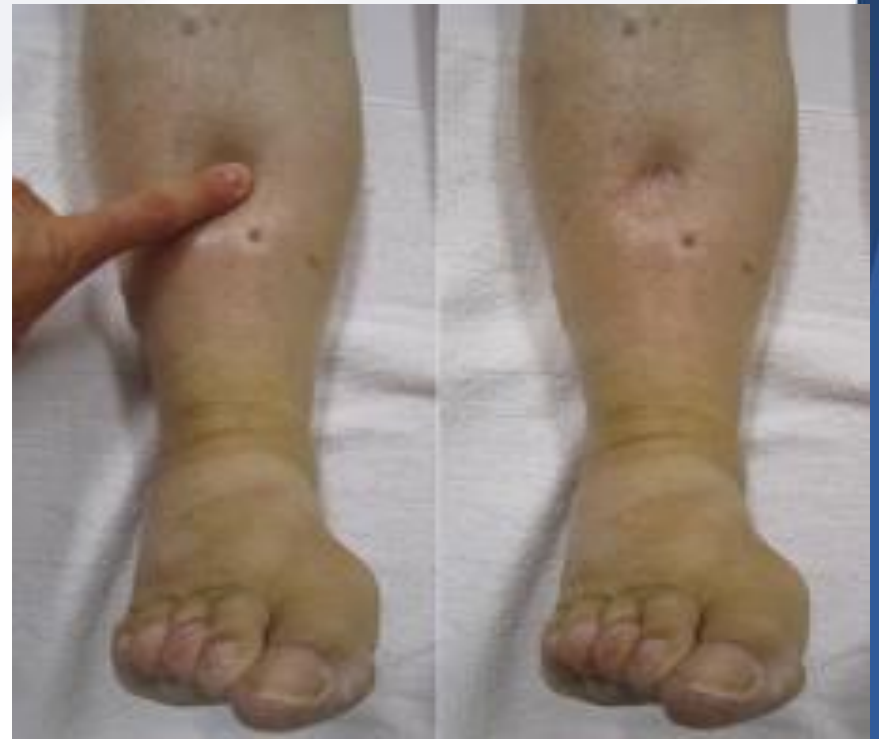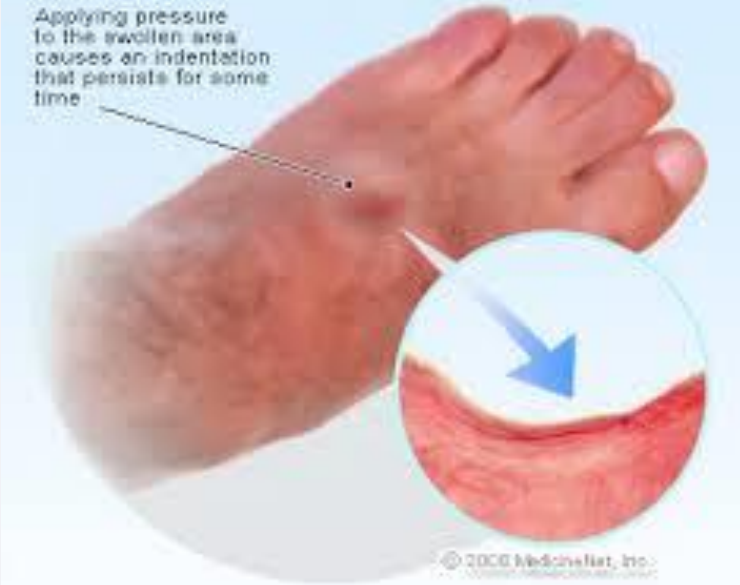Palpation

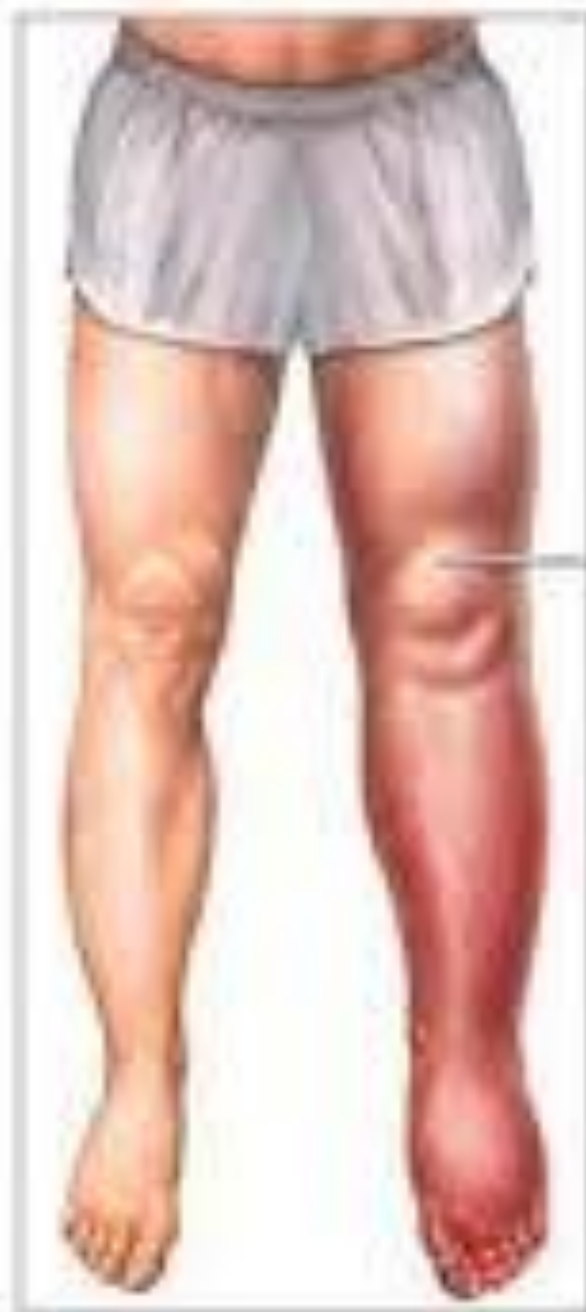

- Palpation
 - Edema
 - Usually not detectable until interstitial fluid volume is 30% above normal (7-10lbs)

Pitting Edema

Applying pressure to the swollen area causes an indentation that persists for some time



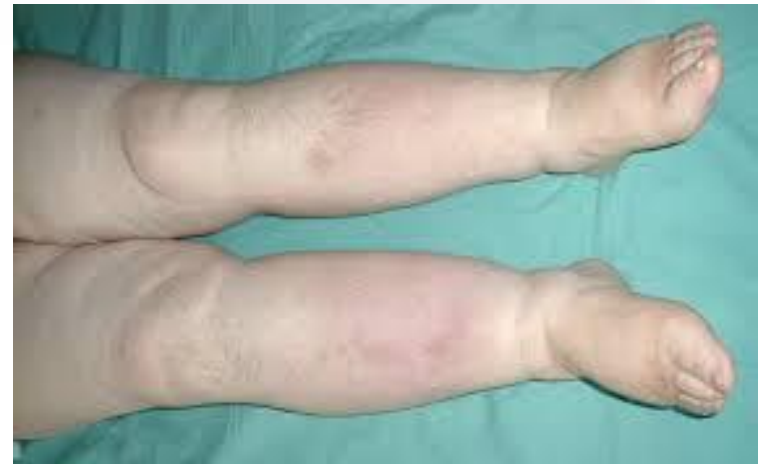
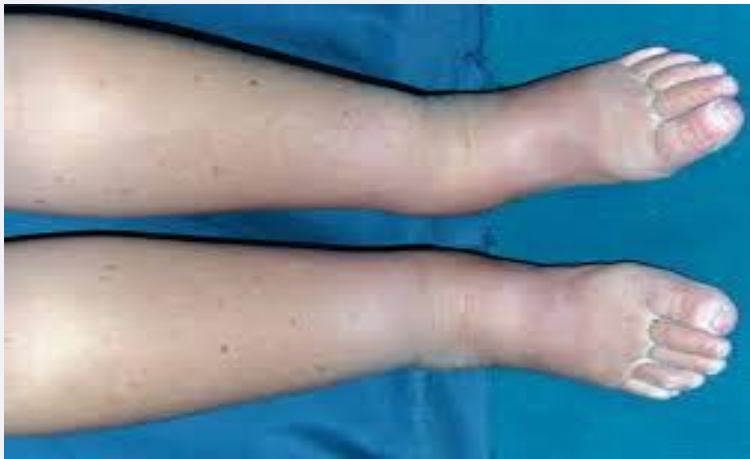
Edema or swelling
of the leg, ankle
and foot

Palpation - Edema

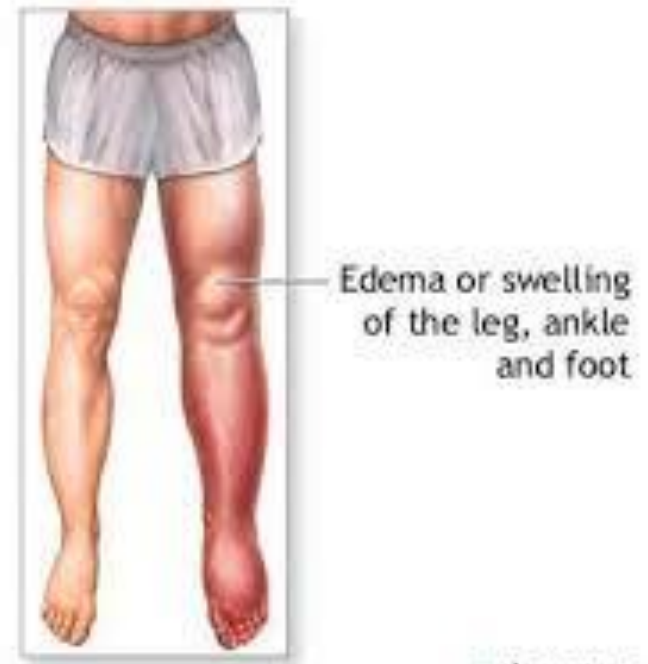
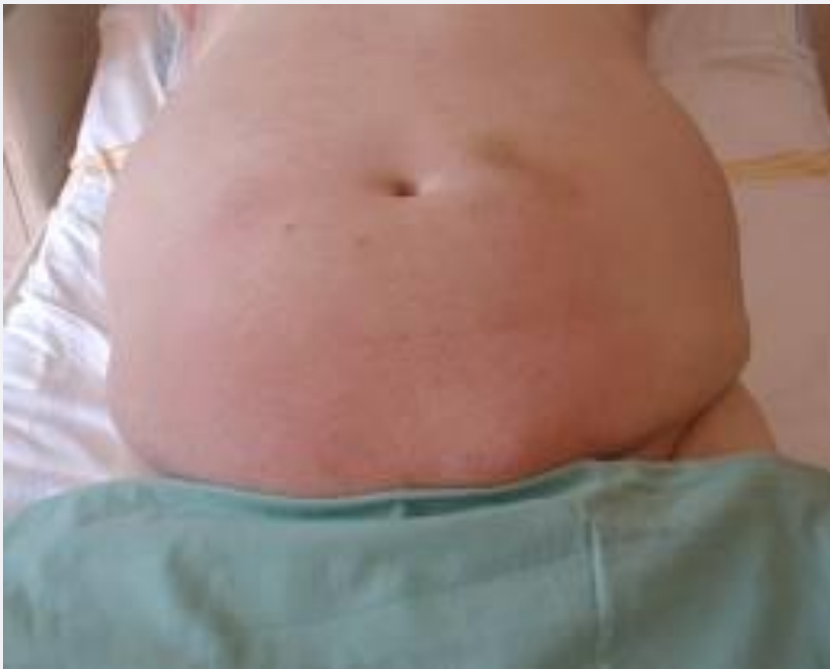

- Bilateral edema
 - Progression from ankles, legs, thighs, genitalia, and abdomen
 - Indicative of heart failure or bilateral venous insufficiency (unilateral seen in venous thrombosis and lymphatic blockage of extremity)

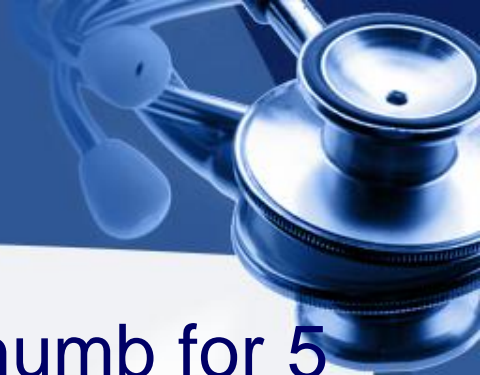

Palpation

- Anasarca
 - Generalized edema
 - Seen in severe heart failure, hepatic cirrhosis, and nephrotic syndrome

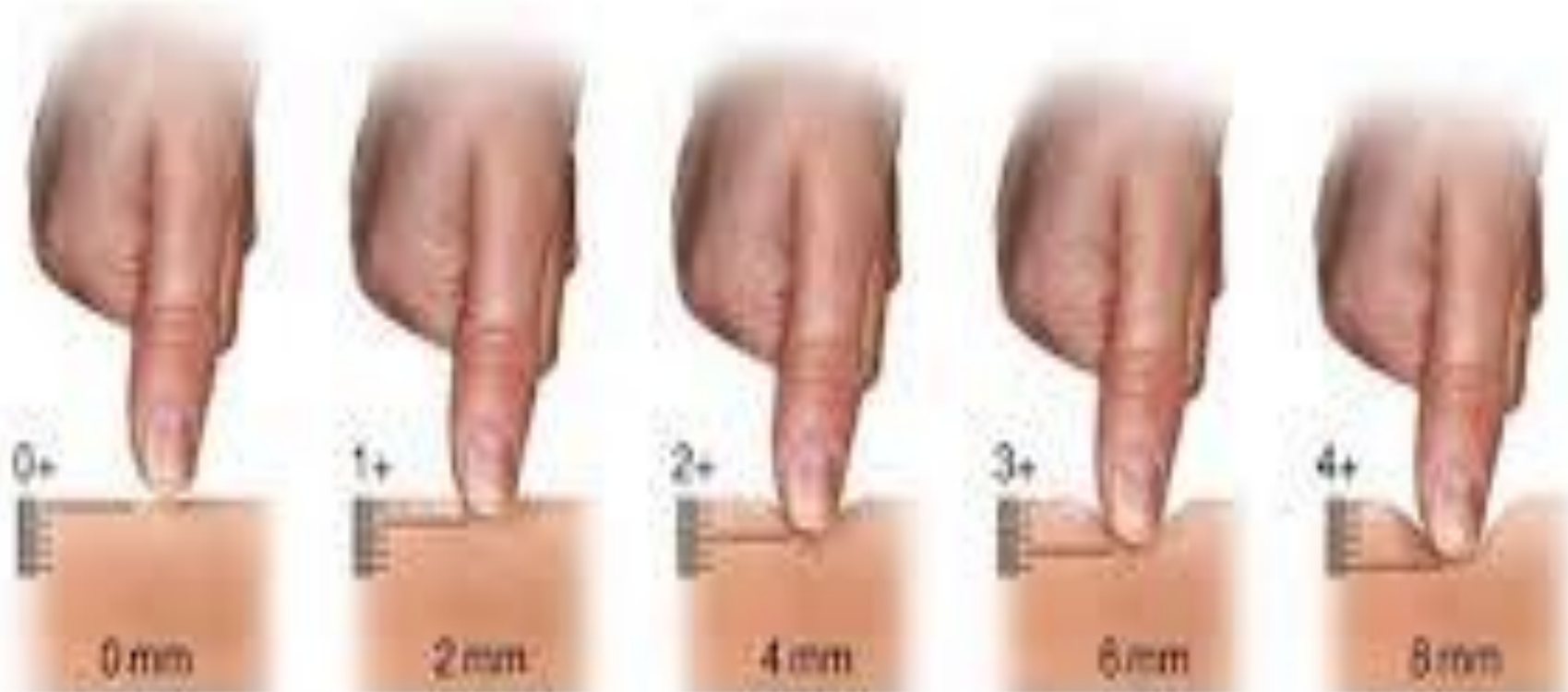


Palpation



- Edema scale : evaluated by pressing thumb for 5 seconds
 - 0 = absent
 - +1 = slight indentation
 - disappears rapidly
 - +2 = indentation readily noticeable
 - disappears within 10-15 seconds
 - +3 = deep indentation
 - disappears within 1-2 minutes
 - +4 = marked, deep indentation
 - may be visible in >5min

Edema



0+ No pitting edema

1+ Mild pitting edema. 2 mm depression that disappears rapidly.

2+ Moderate pitting edema. 4 mm depression that disappears in 10–15 seconds.

3+ Moderately severe pitting edema. 6 mm depression that may last more than 1 minute.

4+ Severe pitting edema. 8 mm depression that can last more than 2 minutes.

Palpation



- Skin Turgor
- Arterial Pulses
 - Rate and rhythm
 - Pulse volume
 - Simultaneous bilateral evaluation required
 - Common abnormalities
 - Weak, thready pulse
 - one that is very fine and scarcely perceptible

Palpation



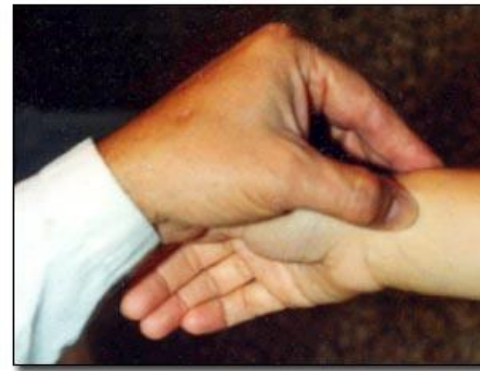- Pulse volume
 - Bounding pulse
 - a pulse that feels full and springlike on palpation as a result of an increased thrust of cardiac contraction or an increased volume of circulating blood within the elastic structures of the vascular system
 - Pulsus alternans
 - alternating beats are so weak as to be undetected, causing apparent halving of the pulse rate
 - Bigeminal pulse
 - Pulsus Paradoxus – strong on expiration, weak on inspiration ; present if difference in systolic pressure varies > 15 mm Hg between inspiration and expiration

Palpation



- Pulse volume
 - Bigeminal pulse
 - Two beats occur in rapid succession, the groups of two being separated by a longer interval
 - Pulsus Paradoxus
 - Strong on expiration, weak on inspiration
 - absent if difference in systolic pressure varies > 15 mm Hg between inspiration and expiration

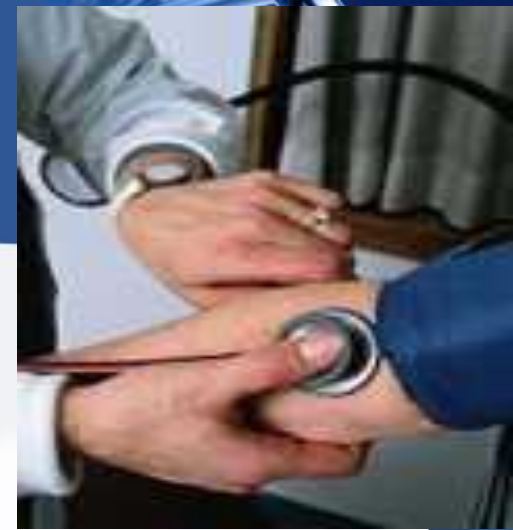Palpation



- Pulse Rating
 - 0 = absent, may be heard with doppler
 - 1 = feeble, difficult to palpate, fades in and out
 - 2 = faint, easily obliterated
 - 3 = normal, easily palpated, not easily obliterated
 - 4 = bounding, strong, hyperactive, not obliterated by pressure
 - D = doppler only

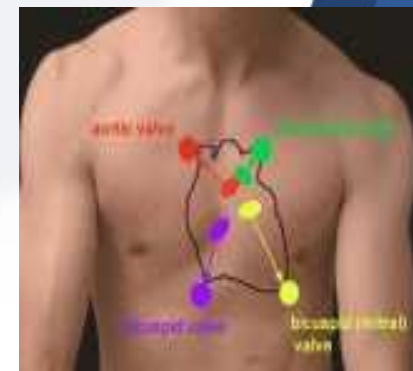
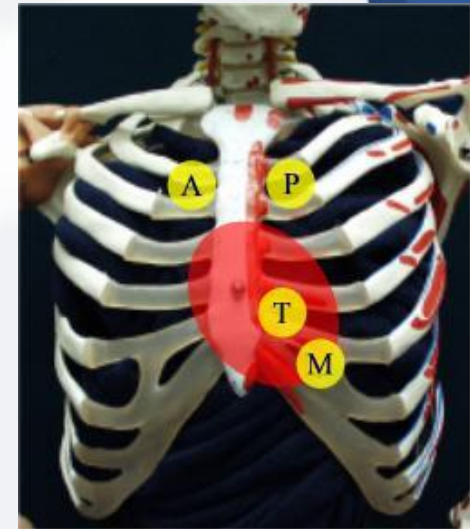
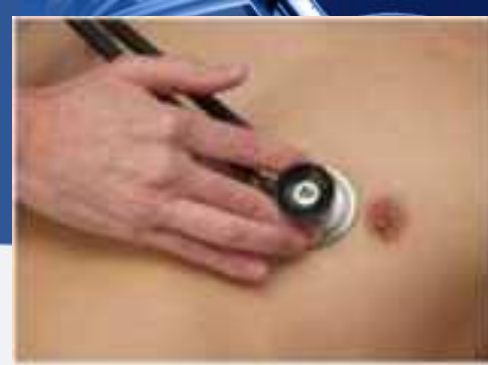Auscultation

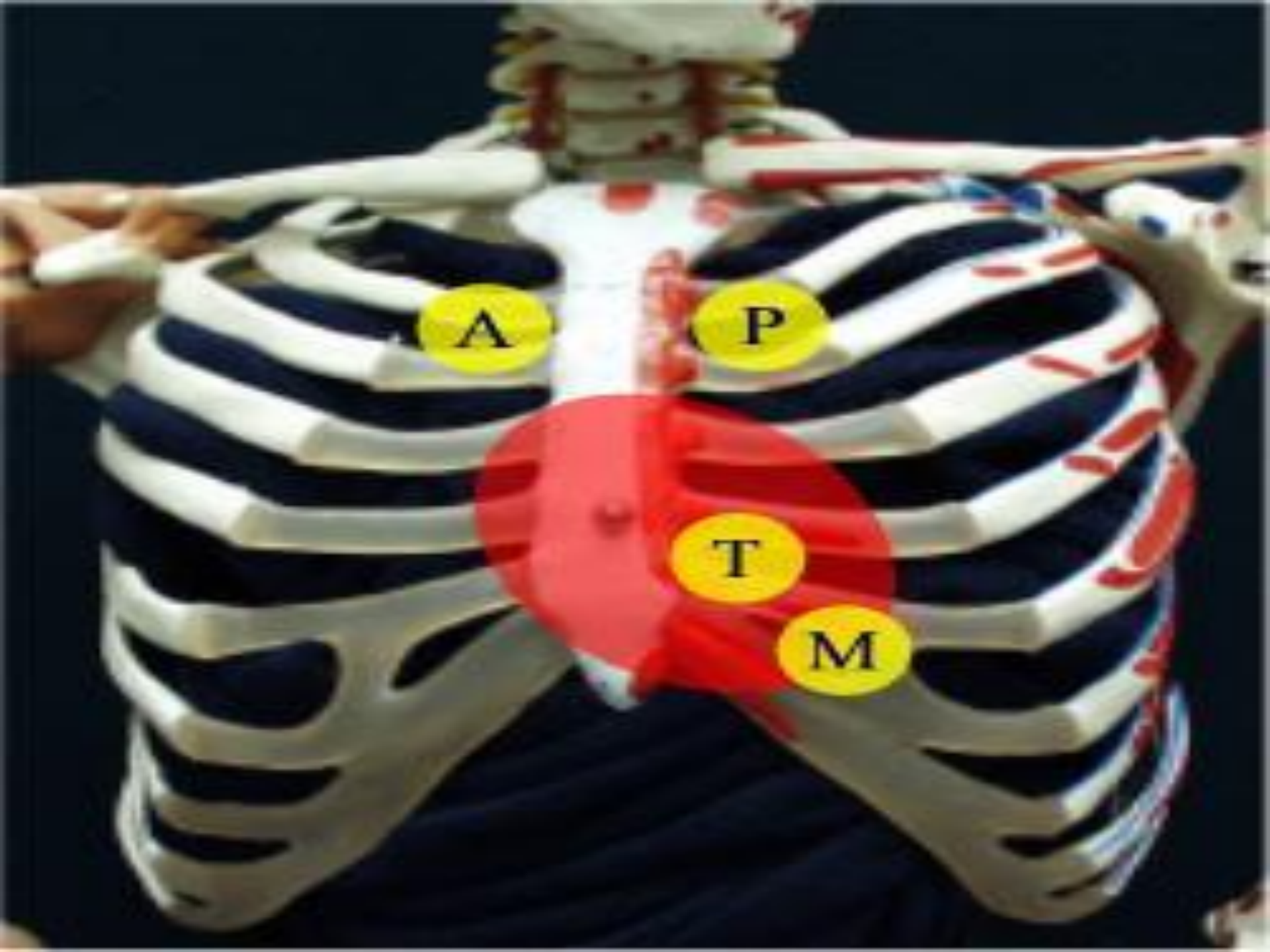
- Auscultation
 - Blood pressure
 - Overall reflection of LV function
 - Systolic represents force of contraction
 - Diastolic represents vascular resistance (afterload)
 - Pulse pressure – difference between systolic and diastolic
 - Widening
 - Narrowing
 - Orthostatic changes – minimum 3 minutes wait ;
>10mm Hg drop



Auscultation

- Heart Borders
- Specific areas for examination
 - Aortic area: 2nd ICS, RSB
 - Pulmonic area: 2nd ICS, LSB
 - Tricuspid area: 5th ICS, LSB
 - Mitral or Apical area: 5th ICS, MCL
 - Erb's point: 3rd ICS, LSB
 - Epigastric : over xyphoid process





A

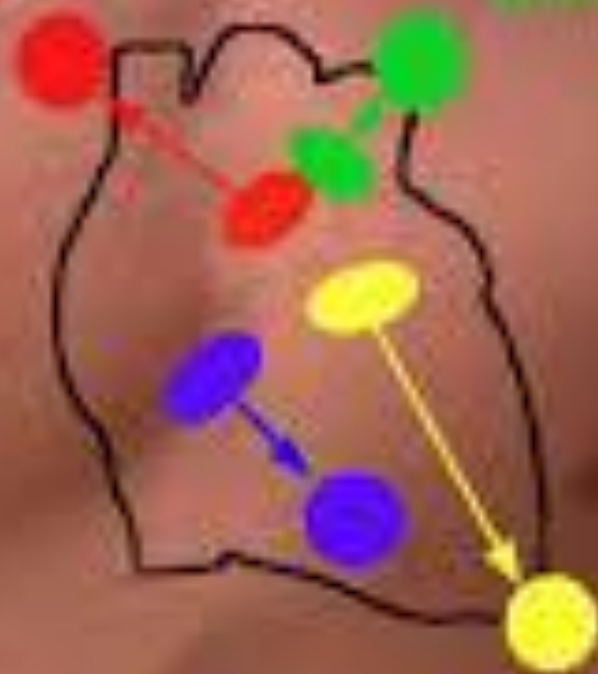P

T

M

aortic valve

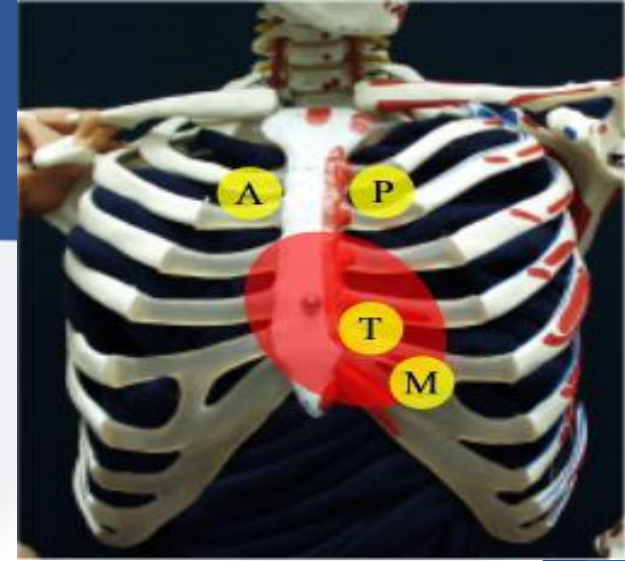
pulmonary valve



tricuspid valve

bicuspid (mitral)
valve

Auscultation



- Heart Sounds - Closure of Valves
 - S1
 - first heart sound “lub”
 - closure of AV valves heard loudest at mitral and tricuspid areas
 - usually lower pitch than S2
 - S2
 - second heart sound “dub”
 - closure of semilunar valves
 - heard best at aortic and pulmonic areas

Auscultation



- Heart Sounds - Closure of Valves
 - S3
 - Ventricular gallop
 - Heard in early diastole, just after S2
 - Due to rapid, early ventricular filling
 - Indicates loss of ventricular compliance, diastolic overloading, heart failure
 - Heard best
 - bell, mitral area if produced by left heart
 - along sternal borders if produced by right heart

Auscultation



- S4
 - Atrial gallop
 - Heard in late diastole, just before S1
 - Results when ventricular resistance to atrial filling increased from decreased ventricular compliance or increased ventricular volume
 - Seen in: ventricular hypertrophy, ischemic heart disease, MI, hypertension, mitral regurgitation

Auscultation



- Summation Gallop
 - Presence of all four sounds. S3 and S4 merge into one sound
 - Occurs at rates > 100
 - Occurs in heart failure

Auscultation - Murmurs



- Murmurs
 - Produced by increased or turbulent blood flow
 - Often imply significant disease of heart valves, great vessels, or septal defects
 - Classified by the following characteristics
 - Timing: systolic or diastolic
 - Pitch: high or low
 - Quality: blowing, harsh, musical, rumbling
 - Intensity: graded from I-VI

Murmur - Intensity



I = barely audible

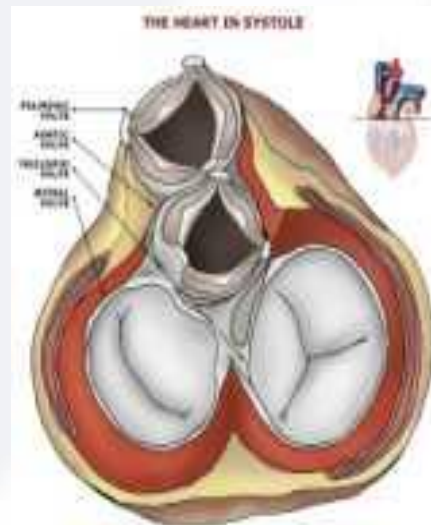
II = faint, but immediately available

III = easily audible

IV = loud, usually accompanied by thrill

V = very loud, always accompanied by thrill

VI = very loud, can be heard with stethoscope off chest



Murmurs

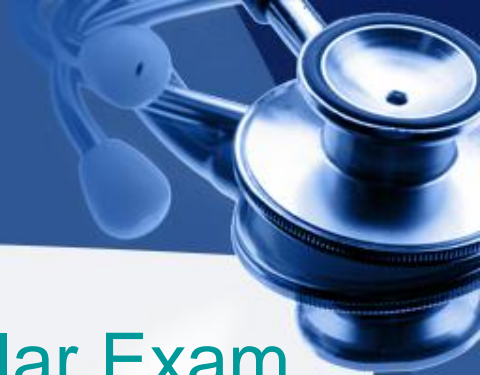

- Innocent Murmurs
 - Hemodynamically insignificant, physiologic
 - Not associated with cardiac disease
 - Common in children and pregnant women
 - Found in hyperthyroidism, anemia

Extracardiac Sounds



- Pericardial Friction Rubs
 - Caused by inflammation of pericardium
 - Rough, scratchy, squeaky sound “like two pieces of leather rubbing against each other
 - Best heard with patient leaning forward, holding breath in full expiration
- Clicks
- Mediastinal crunch
- Systolic snap
- Venous hum



- The Cardio Vascular / Peripheral Vascular Exam

