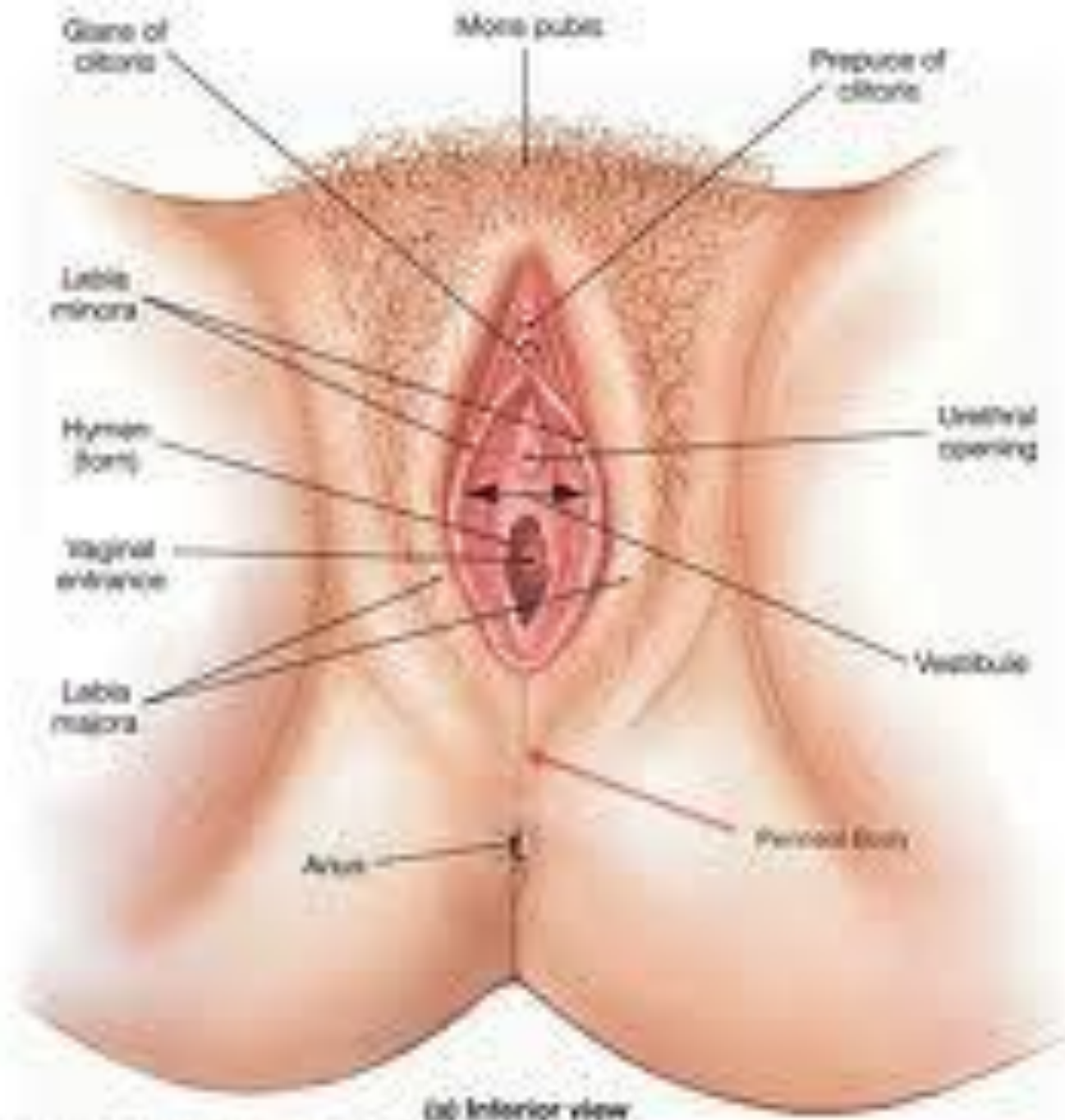




# **Examination of Female Genitalia**

**Dr. Gary Mumaugh – Western Physical Assessment**



# Gynecologic History



- Ask about age of menarche (1<sup>st</sup> menses)
  - In USA the range is between 9-16
- Ask about menstruation patterns
  - How often menses? (24-32 cycle normal)
  - How long is menses? (3-7 days normal)
  - How heavy is menses?
    - Number of pads and tampons used is an indicator
- If applicable, age of menopause.

# Gynecologic History



- Amenorrhea – absence of menses
  - Primary amenorrhea
    - Failure of menses to start
  - Secondary amenorrhea
    - Cessation of periods after they have already existed
    - Physiological causes, pregnancy, breast feeding, menopause, pituitary tumor, anorexia nervosa, pathological causes, hypothyroidism

# Gynecologic History



- Dysmenorrhea
  - Painful periods
  - In lower pelvis and low back
- PMS – Pre Menstrual Syndrome
  - Complex symptoms occurring 4-10 days before the onset of menses
  - Psychological symptoms include tension, irritability, depression and mood swings
  - Physical symptoms of weight gain, bloating, edema, headaches and breast tenderness

# Gynecologic History



- Polymenorrhea
  - Having too frequent menses
- Menorrhagia
  - Increased amount of bleeding or duration of flow
  - Bleeding that occurs between periods

# Gynecologic History



- Ask about pregnancies
  - How many total pregnancies?
  - How many births were term?
  - Preterm?
  - Miscarriages?
  - Abortions?
  - Any complications in prenatal care, labor and delivery?
  - Birth control used?

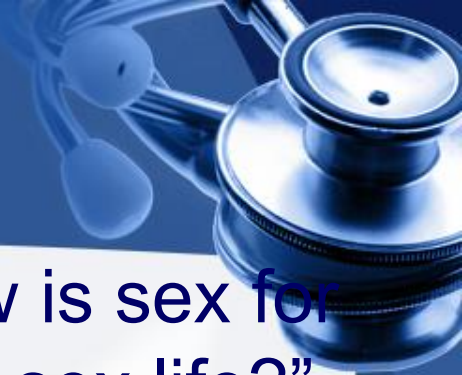# Gynecologic History



- Ask about vulvovaginal symptoms including burning, itching, and the quantity and quality of discharge (including texture, amount, color and smell)
- Ask about sexual preference and sexual response
  - Be professional and matter of fact in questioning and never assume that all patients are heterosexual



# Gynecologic History



- Ask open ended questions such as “How is sex for you?” “Is your partner satisfied with your sex life?”
- Ask about symptoms of sexual dysfunction
  - Lack of interest
  - Lack of physiological response to desire
    - Decreased lubrication
  - Lack of orgasm
  - Dyspareunia or painful intercourse
  - Vaginismus or spasms of the muscles around the vagina making penetration difficult

# Physical Examination of Female Genitalia



- The Patient
  - Avoid intercourse or douching 1-2 days prior to exam
  - Empty bladder before exam
  - Lie on back with head and shoulders elevated
  - Arms at side or folded on abdomen to reduce abdominal muscle tightening

# Physical Examination of Female Genitalia



- The Practitioner
  - Obtain permission
  - Explain each step of the examination in advance. Have a chaperone.
  - Drape patient from abdomen to knees
  - Avoid sudden movement
  - Choose appropriate size speculum
  - Warm speculum with water
  - Monitor the comfort of the examination by observing patient's face
  - Use gentle insertion of speculum

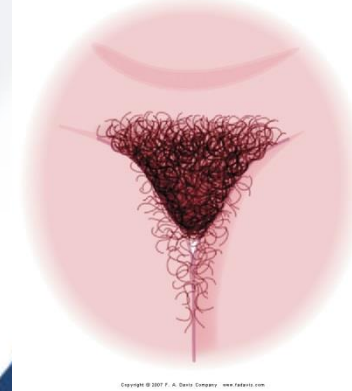
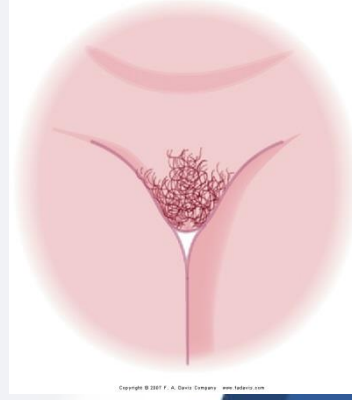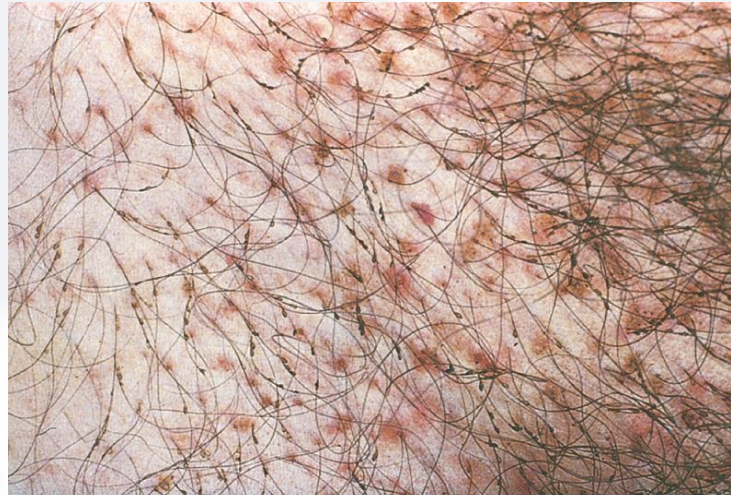
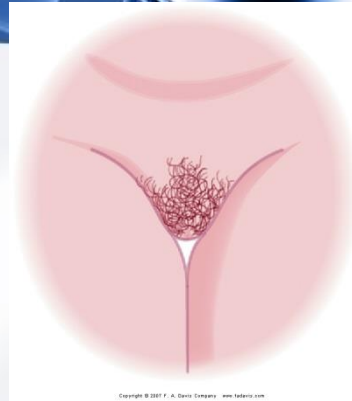
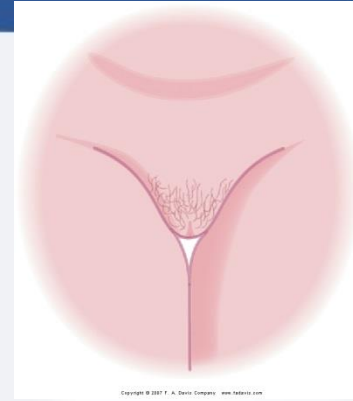
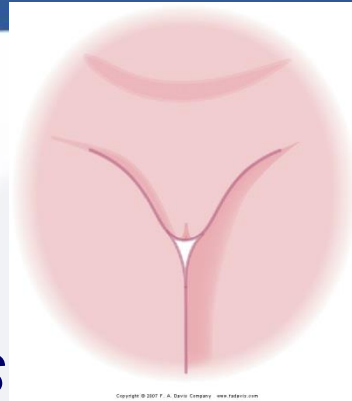
# Proper Sequence of Female Genital Examination

- Examine external genitalia
- Perform speculum examination
- Perform bimanual examination
- Perform rectovaginal examination
- Perform rectal examination



# Inspection

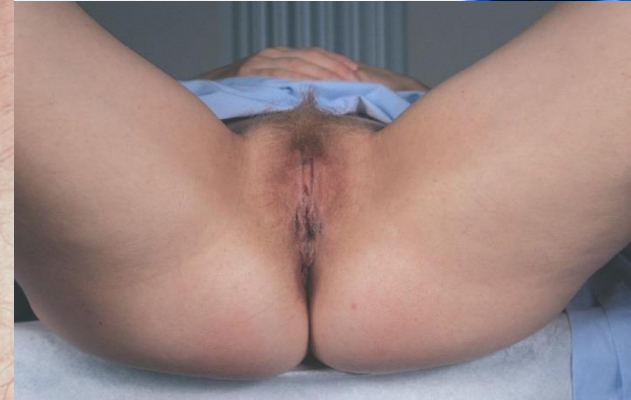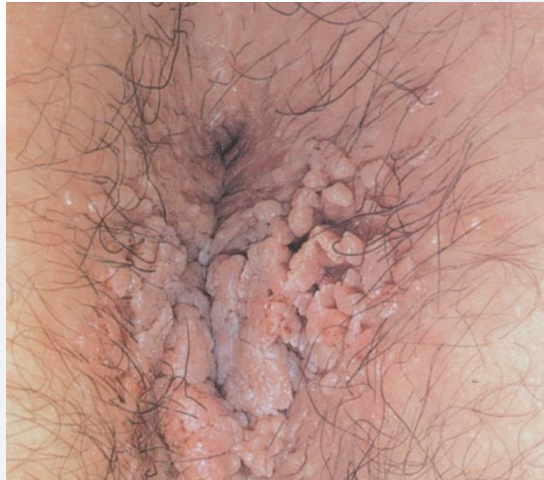- Skin color
  - *No suspicious pigmented lesions noted.*
- Hair distribution
  - *Inverted triangle.*
  - *No nits or lice.*
  - Tanner staging for adolescence



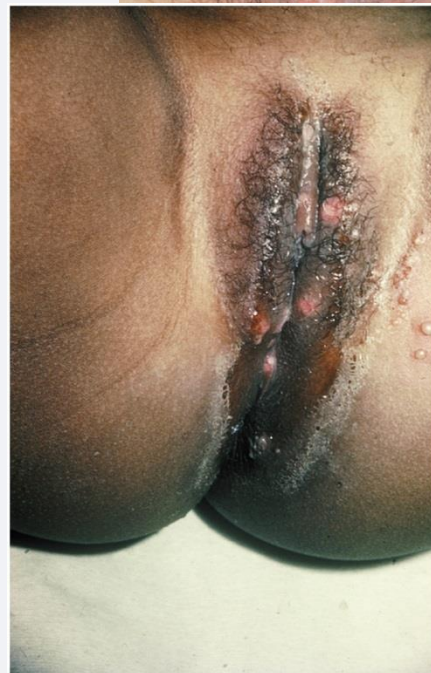# Inspection



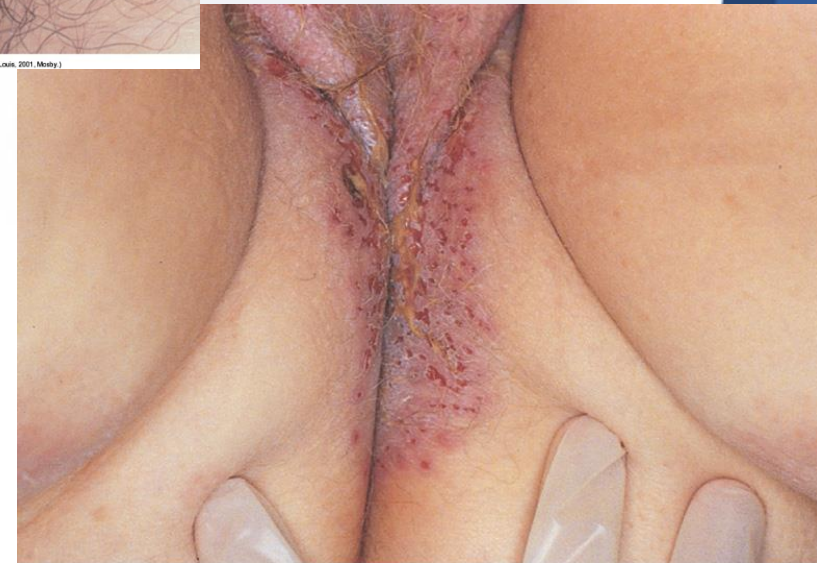- Labia majora
  - Symmetrical
  - ,excoriation,
  - nodules,
  - rash,
  - lesions or
  - edema
- Perineum
  - Smooth
  - Well healed
  - episiotomy
  - scar



Elsevier items and derived items © 2008, 2004, 2001, 1996, 1992 by Saunders, an imprint of Elsevier Inc.



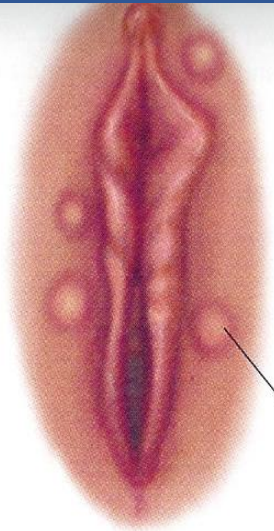
ed 3, St. Louis, 2001, Mosby)



(From Callen JP et al: Color atlas of dermatology, Philadelphia, 1993, W. B. Saunders.)

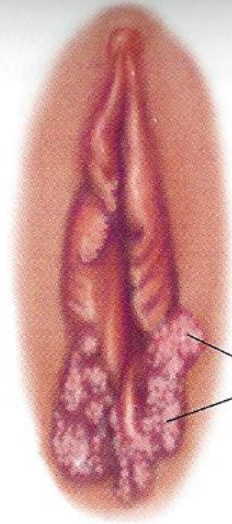
Copyright © 2007 F. A. Davis Company www.fadavis.com

# Female Abnormalities



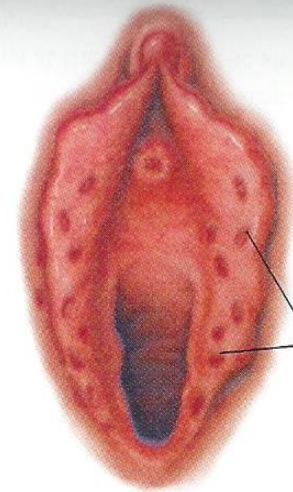
Cystic nodule  
in skin

**Epidermoid Cyst**



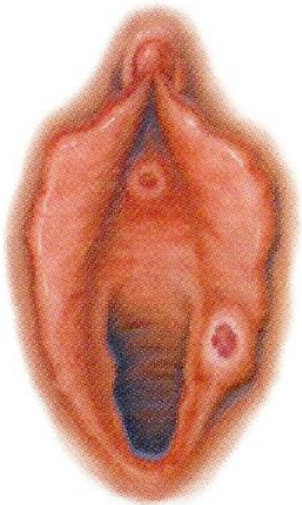
Warts

**Venereal Wart**

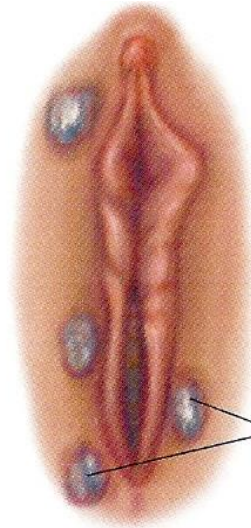

Shallow ulcers  
on red bases

**Genital Herpes**

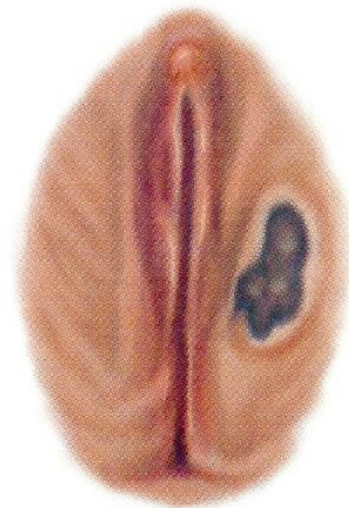


**Syphilitic Chancre**



Flat, gray  
papules

**Secondary Syphilis**  
(*Condyloma latum*)



**Carcinoma of the Vulva**

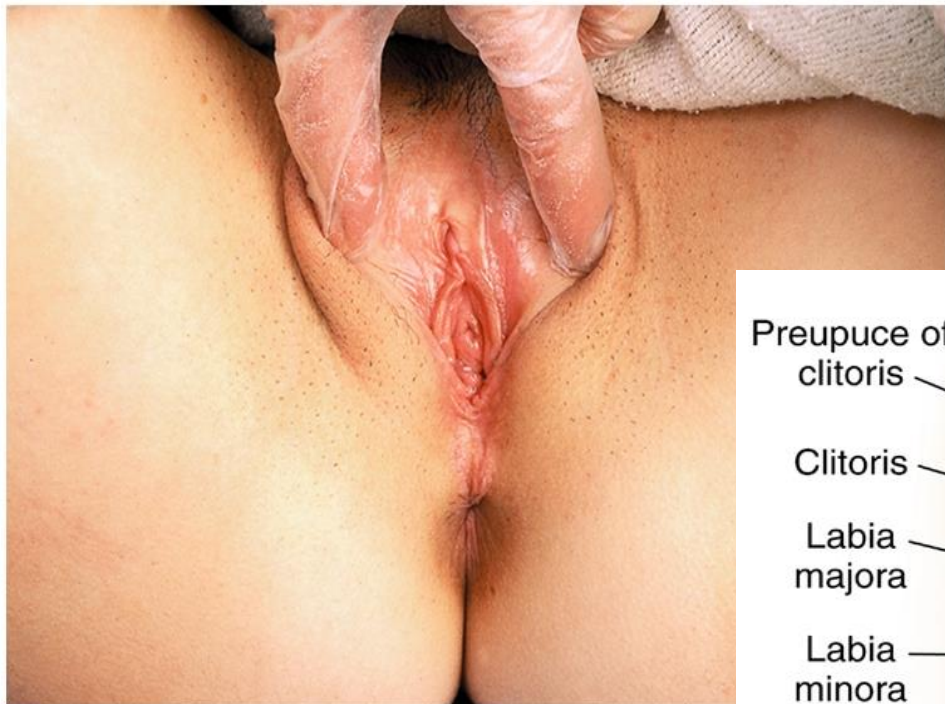
# Inspection



- With gloved hand separate labia major and inspect:
    - Clitoris
    - Labia minora
      - Dark pink and moist
    - Urethral opening
      - Slitlike and midline
    - Vaginal opening
      - No discharge or foul odor
- No excoriation, nodules, rash, lesions, or edema.*



# Inspection



Copyright © 2007 F. A. Davis Company www.fadavis.com

Prepuce of clitoris

Clitoris

Labia majora

Labia minora

Bartholin's glands

Perineum

Anus

Urethral orifice

Skene's ducts

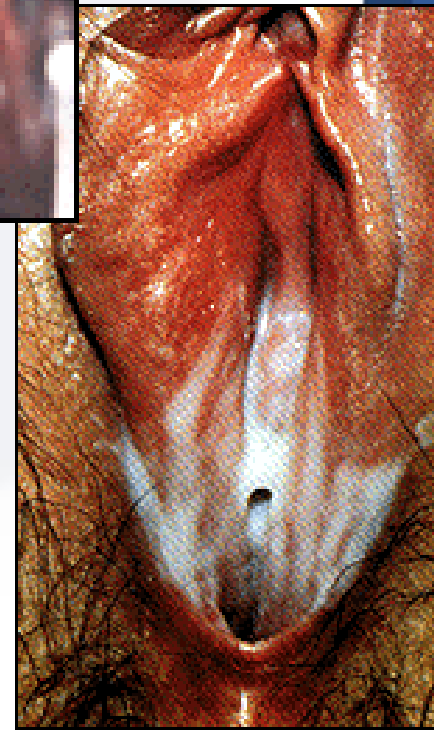
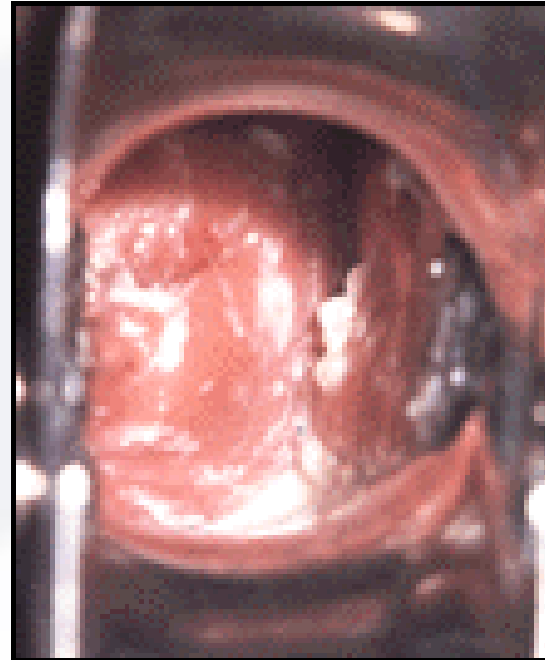
Vaginal orifice

Hymen

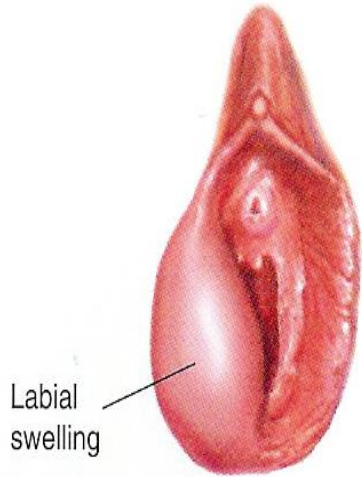
Copyright © 2007 F. A. Davis Company www.fadavis.com

# Discharge

- Candidiasis- thick, white curdy
- BV- thin, creamy gray-white; foul smelling
- Trichomoniasis- frothy yellow-green; foul smelling
- Chlamydia- White mucopurulent
- Gonorrhea- yellowish

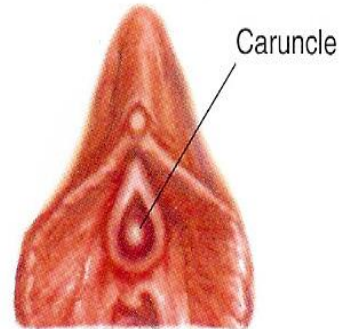


# Female Abnormalities



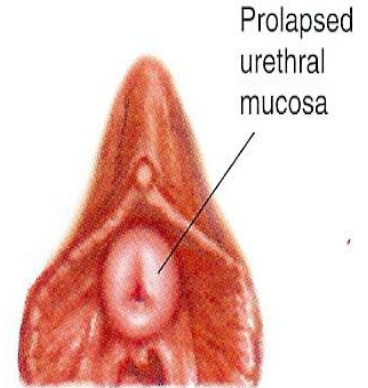
Labial swelling

**Bartholin's Gland Infection**



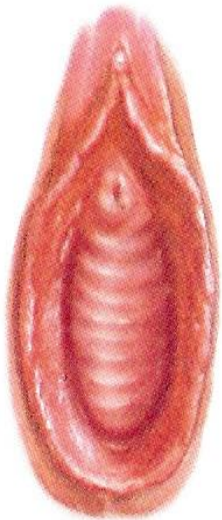
Caruncle

**Urethral Caruncle**

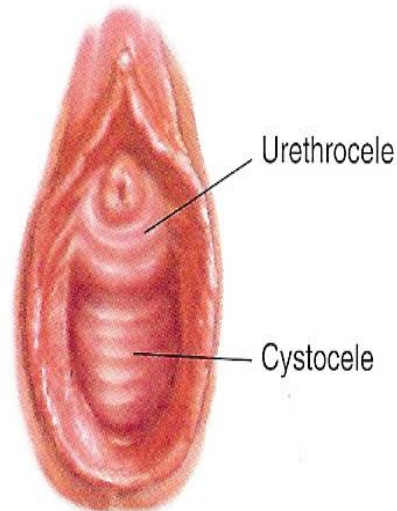


Prolapsed urethral mucosa

**Prolapse of the Urethral Mucosa**



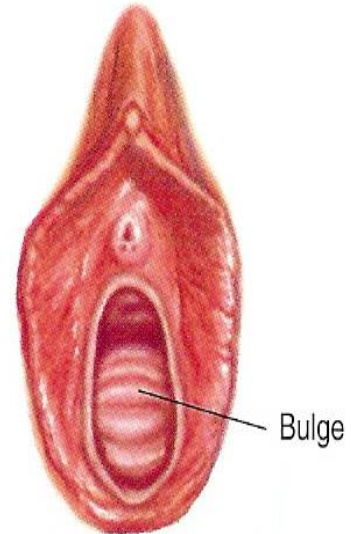
**Cystocele**



Urethrocele

Cystocele

**Cystourethrocele**

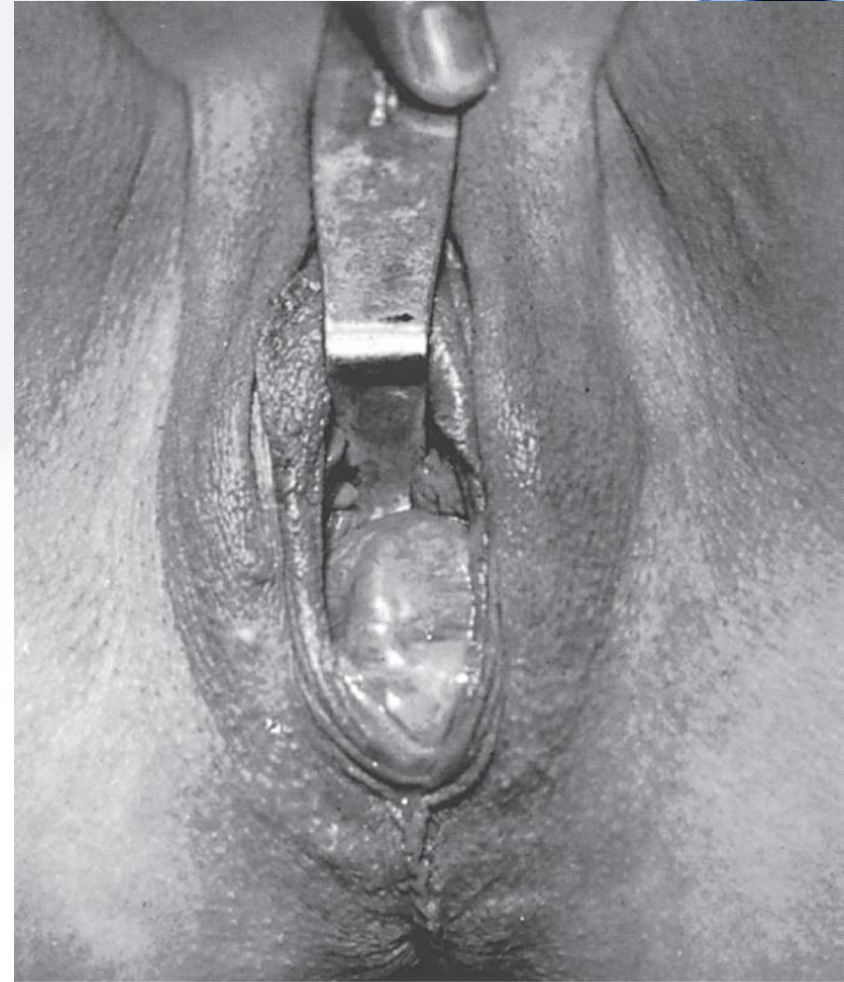
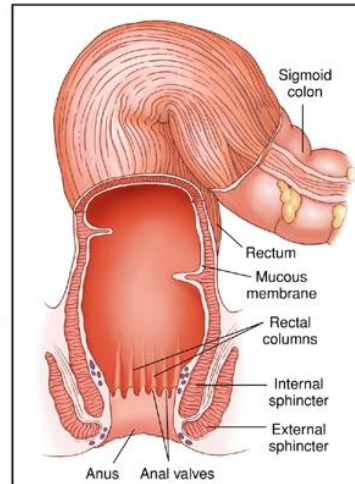
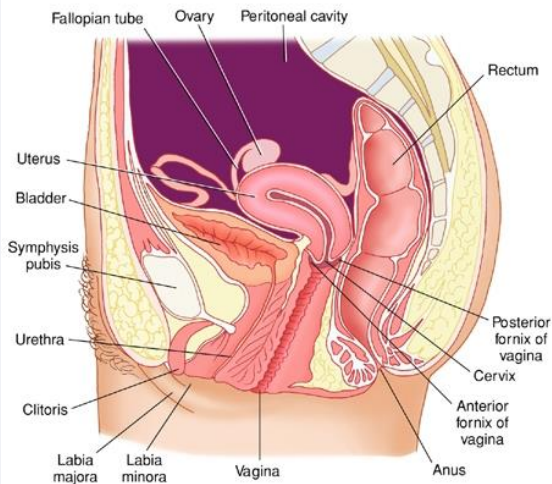


Bulge

**Rectocele**

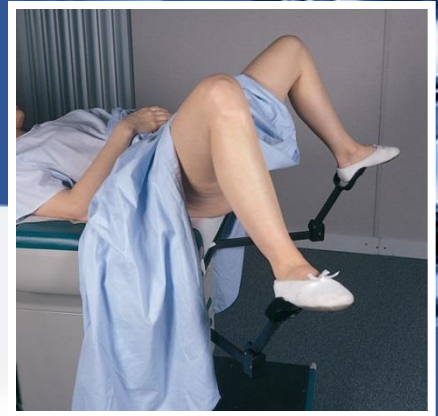# Female Abnormalities

- Rectocele
- Cystocele
- Uterine prolapse



(From Huffman JW: *Gynecology and obstetrics*, Philadelphia, 1962, W. B. Saunders.)

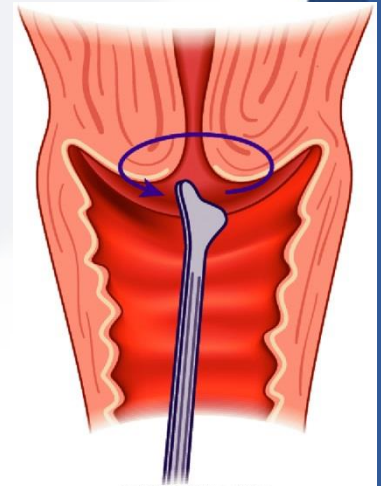
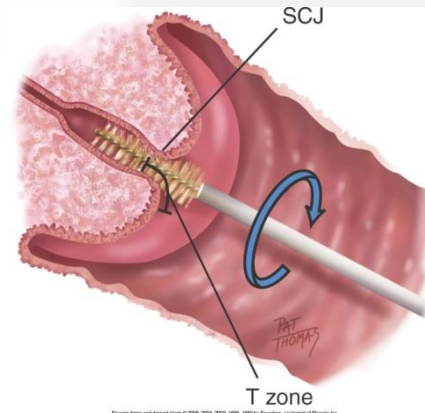
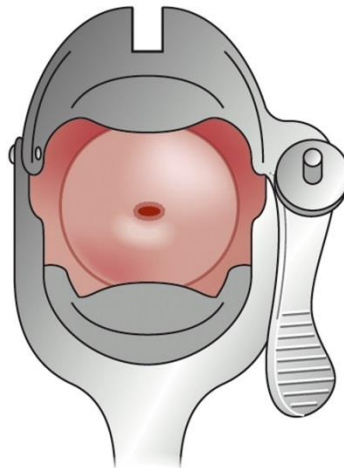
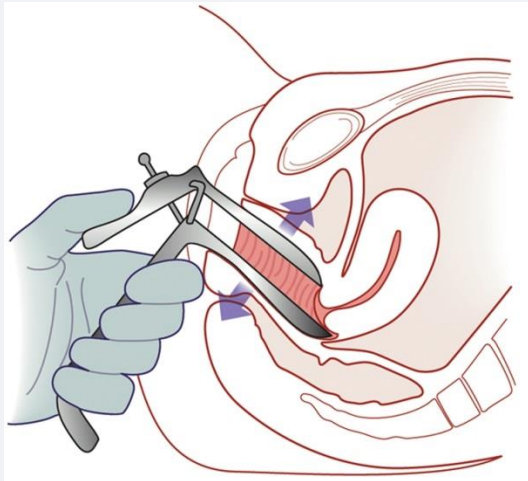
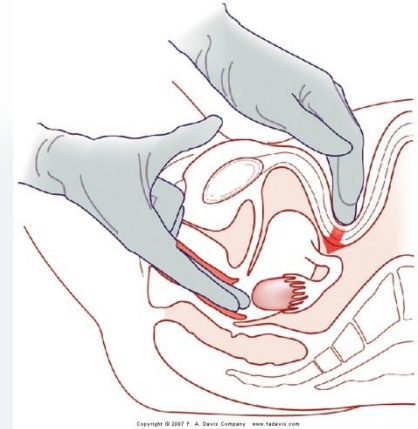
# Speculum Examination



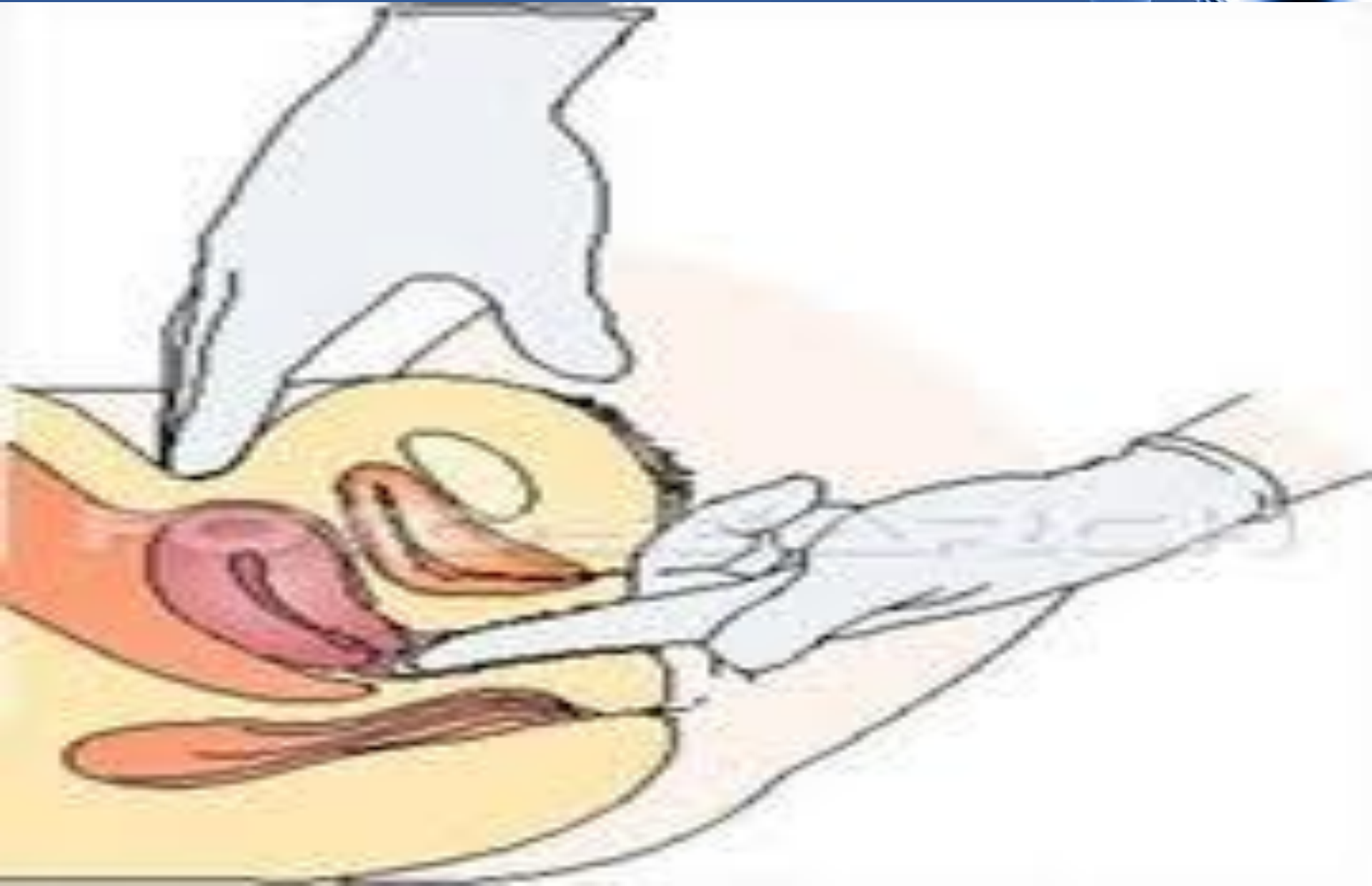
- For routine pelvic exams patient should not be on menses
- Patient should avoid intercourse, douching, vaginal suppositories and tampons 24 hours prior to exam
- Have patient empty bladder before examination
- Patient lies supine, with head and shoulders elevated
- Have patient place heels in stir-ups, slide all the way down examination table until buttocks extend slightly beyond the edge
- Thighs should be flexed, abducted and externally rotated at the hips
- Have light source available and supplies accessible

# Speculum Examination/Bimanual Palpation

- Obtain cervical smears and cultures
  - Pap Smears for cervical cancer
- Inspect vaginal wall and cervix
- Palpate cervix, uterus & ovaries



# Bimanual Exam



# Rectovaginal Exam



- Rectovaginal exam has three purposes
  - Palpate a retroverted uterus, the uterosacral ligaments, cul-de-sac, and adnexa
  - Screen for colorectal cancer
  - Assess pelvic pathology
- Glove the dominant hand and lubricate the index finger
- Place the index finger of the dominant hand inside the vagina and the middle finger in the anus and have the patient bear down



# Female Rectal Exam

- Gently place the finger in the anus
- Palpate for hemorrhoids and masses
- If needed, check for occult blood with a hemoccult test
- Wipe off the external genitalia and anus with gauze or tissue. Give her some to clean herself after the exam.
- Always ask the patient to get dressed before discussing any findings.
- Unclothed patients have a hard time concentrating.



# Special Circumstances



- Urethritis
  - If you suspect urethritis or inflammation of paraurethral glands, insert your index finger into the vagina and milk the urethra gently from inside outward
  - Culture any discharge that has been milked out

# Charting



- *SUBJECTIVE*

- Menarche age 12, cycle usually q 28 days, duration 5 days, flow moderate, no dysmenorrhea, LMP April 3. Grav 0/Para 0/Ab 0.

Gyn checkups yearly. Last Pap test 1 year PTA, negative.

- No urinary problems, no irritation or foul-smelling vaginal discharge, no sores or lesions, no history pelvic surgery. Satisfied with sexual relationship with husband, uses vaginal diaphragm for birth control, no plans for pregnancy at this time. Aware of no STD contact to self or husband.

# Charting



- OBJECTIVE

- External genitalia—no swelling, lesions, or discharge. No urethral swelling or discharge. Internal—vaginal walls have no bulging or lesions, cervix pink with no lesions, scant clear mucoid discharge.

- Bimanual—no pain on moving cervix, uterus anteflexed and anteverted, no enlargement or irregularity. Adnexa—ovaries not enlarged. Rectal—no hemorrhoids, fissures or lesions, no masses or tenderness, stool brown with guaiac test negative.

# Female Genitourinary Videos



- [Nursing Assessment: The Female Genitourinary System](#)
- [Female Pelvic Exam](#)